Turkish Journal of Clinical Research

Turk J Clin Res. 2026;2(1):22-30
https://doi.org/10.63909/1453040

RESEARCH ARTICLE

Ultrasound-guided proximal C2 greater occipital nerve block in chronic migraine: Imaging landmarks and short-term clinical outcomes

Kronik migren hastalarında ultrason rehberliğinde proksimal C2 düzeyinde büyük oksipital sinir bloğu: Görüntüleme landmarkları ve kısa dönem klinik sonuçlar

Emel BASAR[1], Nevcihan SAHUTOGLU BAL[2]

[1]Giresun Training and Research Hospital, Department of Pain Medicine, Giresun, Türkiye
[2]Ankara Bilkent City Hospital, Department of Pain Medicine, Ankara, Türkiye

Abstract

- **Aim:** To evaluate the short-term effectiveness and safety of ultrasound-guided proximal C2 greater occipital nerve block in patients with chronic migraine.
- **Methods:** This single-center, retrospective observational study included 41 consecutive adults with chronic migraine diagnosed according to the International Classification of Headache Disorders, 3rd edition (ICHD-3), who underwent ultrasound-guided greater occipital nerve block at the proximal C2 level in the Department of Pain Medicine. Pain intensity, monthly headache days, monthly number of days with headache severity > 5, attack duration, and patient-reported outcomes (HIT-6 and GPE) were assessed at baseline and at the 1st week, 1st month, and 3rd month follow-up visits. Changes over time were analyzed using appropriate non-parametric tests for repeated measures.
- **Results:** Monthly headache days, monthly number of days with headache severity >5, pain intensity, and attack duration were significantly lower at the 1st and 3rd months than at baseline (all p<0.001). GPE scores did not differ significantly during follow-up (p=0.059). HIT-6 scores were significantly lower at the 1st and 3rd months than at baseline (both p<0.001), with no significant difference between the 1st and 3rd months (p=1.000). When a Likert score of 2 was defined as treatment success, the success rate increased significantly across follow-up visits (Cochran's Q test, p <0.001), from 7.3% at the 1st week to 36.6% at the 3rd month. No major procedure-related complications were observed.
- **Conclusion:** Ultrasound-guided greater occipital nerve block performed at the proximal C2 level appears to be a safe and clinically useful short-term treatment option in patients with chronic migraine. This approach was associated with reductions in headache burden, pain severity, and headache-related disability, with increasing patient-reported treatment success over the 3-month follow-up period.
- **Keywords:** Headache disorders, nerve block, cervical vertebrae, pain measurement, retrospective studies.

Özet

- **Amaç:** Kronik migren hastalarında ultrason eşliğinde proksimal C2 düzeyinde uygulanan greater oksipital sinir bloğunun kısa dönem etkinlik ve güvenliğini değerlendirmektir.
- **Yöntem:** Bu tek merkezli, retrospektif gözlemsel çalışmaya, Uluslararası Baş Ağrısı Bozuklukları Sınıflaması 3. baskıya (ICHD-3) göre kronik migren tanısı alan ve Ağrı Tıbbı Kliniğinde ultrason eşliğinde proksimal C2 düzeyinde greater oksipital sinir bloğu uygulanan ardışık 41 erişkin hasta dahil edildi. Ağrı şiddeti, aylık baş ağrısı günü sayısı, aylık şiddeti >5 olan baş ağrısı günü sayısı, atak süresi ve hasta tarafından bildirilen sonuçlar (HIT-6 ve GPE), başlangıçta ve 1. hafta, 1. ay ve 3. ay takiplerinde değerlendirildi. Zaman içindeki değişimler, tekrarlayan ölçümler için uygun non-parametrik testler kullanılarak analiz edildi.
- **Bulgular:** Aylık baş ağrısı günü sayısı, aylık şiddeti >5 olan baş ağrısı günü sayısı, ağrı şiddeti ve atak süresi, 1. ve 3. aylarda başlangıca göre anlamlı olarak daha düşüktü (tümü p<0,001). GPE skorlarında takip süresince anlamlı farklılık saptanmadı (p=0,059). HIT-6 skorları, 1. ve 3. aylarda başlangıca göre anlamlı olarak daha düşüktü (her ikisi için p<0,001); 1. ve 3. ay arasında anlamlı fark yoktu (p=1,000). Likert skoru 2 tedavi başarısı olarak kabul edildiğinde, başarı oranı takip vizitleri boyunca anlamlı olarak arttı (Cochran'ın Q testi, p<0,001) ve 1. haftada %7,3 iken 3. ayda %36,6'ya yükseldi. İşleme bağlı majör komplikasyon gözlenmedi.
- **Sonuç:** Proksimal C2 düzeyinde ultrason eşliğinde uygulanan greater oksipital sinir bloğu, kronik migren hastalarında güvenli ve klinik olarak yararlı bir kısa dönem tedavi seçeneği gibi görünmektedir. Bu yaklaşım, 3 aylık takip süresince baş ağrısı yükünde, ağrı şiddetinde ve baş ağrısına bağlı özürlülükte azalma ile birlikte, hasta tarafından bildirilen tedavi başarısında artış ile ilişkili bulunmuştur.
- **Anahtar Kelimeler:** Baş ağrısı bozuklukları, sinir bloğu, servikal vertebra, ağrı ölçümü, retrospektif çalışmalar.

Corresponding Author: Emel BASAR dr_emel86@hotmail.com
Cite as: Basar E, Sahutoglu Bal N. Ultrasound-guided proximal C2 greater occipital nerve block in chronic migraine: Imaging landmarks and short-term clinical outcomes. Turk J Clin Res. 2026;2(1):22-30

Content of this journal is licensed under a Creative Commons Attribution-NonCommercial-NonDerivatives 4.0 International License

Received: 22 April 2026 | **Accepted:** 12 May 2026 | **Published:** 31 May 2026

Turk J Clin Res. 2026;2(1):22-30
https://doi.org/10.63909/1453040

INTRODUCTION

Migraine is a prevalent and multifaceted neurological disorder affecting approximately one in seven individuals worldwide and representing a major contributor to global disability (1). Migraine is generally classified as episodic or chronic based on the number of headache days per month. According to the International Classification of Headache Disorders, 3rd edition (ICHD-3), chronic migraine is defined as headache occurring on at least 15 days per month for more than three months, of which at least 8 days exhibit migrainous features such as pulsating pain, nausea, photophobia, or phonophobia (2). Longitudinal studies indicate that approximately 2.5%–3% of patients with episodic migraine develop chronic migraine within one year. Several clinical and demographic factors have been associated with this progression, including higher headache frequency, medication overuse, obesity, sleep disturbances, and psychiatric comorbidities. Additional factors include female sex, earlier disease onset, lower socioeconomic status, stressful life events, coexisting pain conditions (such as asthma, non-cephalic pain syndromes, head and neck trauma, insomnia, and snoring), caffeine intake, and cutaneous allodynia (3). Pharmacological treatment of migraine typically includes nonsteroidal anti-inflammatory drugs (NSAIDs), antiemetics, and triptans. However, their use may be limited by inadequate symptom relief, treatment-related adverse effects, and contraindications in certain patient groups, such as pregnant or breastfeeding women (4). Medication overuse headache, a secondary headache disorder related to the frequent use of acute migraine medications, is another well-recognized complication of pharmacological treatment (5). Migraine is a clinically heterogeneous disorder with substantial variability in symptoms, comorbidities, and treatment response. This heterogeneity makes it difficult to determine the most appropriate treatment strategy for individual patients and highlights the need for alternative therapeutic approaches (6).

The greater occipital nerve (GON) originates mainly from the medial branch of the dorsal ramus of the second cervical spinal nerve (C2), with variable contribution from C3. After exiting the suboccipital triangle, it courses cranially in an oblique plane between the semispinalis capitis and obliquus capitis inferior muscles (7). This anatomical corridor has been identified as a potential site of nerve irritation or entrapment (8). As it ascends, the nerve pierces the trapezius muscle and courses medial to the occipital artery before supplying sensory innervation to the posterior scalp (7). The GON is thought to have an important role in migraine pathophysiology because of the convergence of trigeminal and upper cervical sensory afferents within the trigeminal nucleus caudalis (9). Injection of a local anesthetic near the greater occipital nerve is thought to modulate trigeminocervical complex activity, thereby reducing headache frequency, intensity, and duration in patients with migraine (10).

In routine clinical practice, many clinicians administer GON injections at the level of the superior nuchal line using a landmark-based technique that relies on superficial osseous anatomical references to deposit local anesthetic and corticosteroid around the nerve. The inherent anatomical uncertainty of this approach increases the likelihood of unintended blockade of adjacent structures or inadvertent intravascular injection, particularly into the occipital artery (8). Although data quantifying these risks remain limited, reported complication rates range from 5% to 10%, including adverse events such as headache, dizziness, blurred vision, and syncope (11).

To address these limitations, ultrasound guidance has increasingly been adopted to enhance procedural safety and optimize the clinical effectiveness of GON injections. Evidence from multiple studies indicates that ultrasound-guided GON blocks performed at the level of the superior nuchal line achieve higher procedural accuracy and are associated with greater improvements in pain scores compared with landmark-based techniques (12).

Although ultrasound-guided greater occipital nerve blocks are increasingly preferred in clinical practice, the short-term clinical outcomes of the proximal C2 approach in patients with chronic migraine have not been sufficiently characterized. The proximal technique allows direct visualization of the nerve within well-defined anatomical planes, potentially offering advantages in terms of procedural accuracy and safety. Therefore, this study aimed to evaluate the short-term effectiveness and safety of ultrasound-guided proximal C2 greater occipital nerve block in patients with chronic migraine.

Turk J Clin Res. 2026;2(1):22-30
https://doi.org/10.63909/1453040

METHODS

Study Design and Setting

This study was designed as a single-center, single-group, retrospective observational study and was conducted at the Algology Unit of Giresun Training and Research Hospital. Approval was obtained from the local Clinical Research Ethics Committee prior to data collection (Approval date and number: 04.03.2026/06). Due to the retrospective nature of the study, all data were obtained from existing medical records generated during routine clinical care, without requiring additional outpatient visits, interventions, or data collection procedures. The study was conducted in accordance with the principles of the Declaration of Helsinki.

Study Population and Sample Selection

The study population consisted of adult patients diagnosed with chronic migraine according to the International Classification of Headache Disorders, 3rd edition (ICHD-3), who underwent ultrasound-guided greater occipital nerve (GON) block at the proximal C2 level in the Algology Unit.

All consecutive patients who met the inclusion criteria during the study period were included in the analysis, yielding a final sample of 41 patients. Patient identification and data extraction were performed through retrospective review of electronic medical records. No control or comparison group was included, and all analyses were conducted within a single study cohort.

To minimize selection bias, all consecutive eligible patients who underwent the procedure during the study period and had complete baseline and follow-up data were included in the analysis. However, due to the retrospective design, potential sources of bias, including selection bias, information bias arising from reliance on medical records, and the absence of a control group, cannot be entirely excluded.

Inclusion Criteria

The study included patients who met all of the following criteria:

- Age between 18 and 65 years
- Diagnosis of chronic migraine according to ICHD-3 criteria
- Insufficient clinical response to at least two migraine preventive treatments (e.g., beta blockers, antiepileptics, antidepressants) and/or botulinum toxin type A (BoNT-A) therapy as documented in medical records
- Having undergone ultrasound-guided greater occipital nerve block in the Algology Unit
- Availability of pre-procedural pain intensity scores (VAS/NRS) and monthly headache day counts in medical records
- Availability of short-term follow-up data documented at the 1st week, 1st month, and 3rd month after the procedure
- Complete procedural documentation, including ultrasound images and/or detailed procedural notes

Exclusion Criteria

Patients were excluded if any of the following criteria were present:

- Missing essential clinical data in medical records (VAS/NRS scores, headache day counts, or follow-up information)
- Documented active infection or skin lesion at the occipital injection site at the time of the procedure
- Known allergy to local anesthetic agents
- Pregnancy or suspected pregnancy
- History of cranial or cervical surgical intervention
- Presence of bleeding diathesis or clinically significant coagulopathy at the time of the procedure
- Presence of secondary causes that could contribute to headache (e.g., intracranial lesions or uncontrolled hypertension)
- Inadequate ultrasound images or insufficient procedural documentation

Ultrasound-Guided Greater Occipital Nerve Block Technique

Greater occipital nerve blocks were performed under ultrasound guidance at the proximal C2 level. As this was a retrospective study, all procedural details were obtained from archived procedure notes and stored ultrasound images.

Turk J Clin Res. 2026;2(1):22-30
https://doi.org/10.63909/1453040

Patients were positioned prone with the head and neck gently flexed to compensate for normal cervical lordosis and to facilitate visualization of upper cervical anatomical landmarks. Following standard skin antisepsis, an Esaote linear ultrasound probe (Esaote, Genoa, Italy) was placed in a transverse orientation over the external occipital protuberance and advanced caudally to identify the single spinous process of C1, followed by the bifid spinous process of C2. After confirmation of the C2 level, the transducer was shifted laterally to visualize the obliquus capitis inferior muscle (OCIM) and the semispinalis capitis muscle (SSCM). At this level, the GON was identified as an oval-shaped hypoechoic structure located within the fascial plane between the OCIM and SSCM. Representative ultrasound landmarks and the in-plane needle trajectory for the proximal C2 approach are shown in Figure 1.

When documented, color Doppler ultrasound was used to assess adjacent vascular structures prior to needle advancement. Using an in-plane technique, a 22-gauge spinal needle was advanced from lateral to medial toward the GON under real-time ultrasound guidance. Correct needle placement within the target fascial plane between the OCIM and SSCM was confirmed sonographically. Following negative aspiration, a total of 2 mL of 0.5% bupivacaine (Buvasin, 5 mg/mL, VEM Pharmaceuticals) was injected on the treated side, and the spread of the injectate surrounding the GON within the fascial plane was visualized. The procedure was performed unilaterally or bilaterally according to clinical presentation, as documented in patient records.

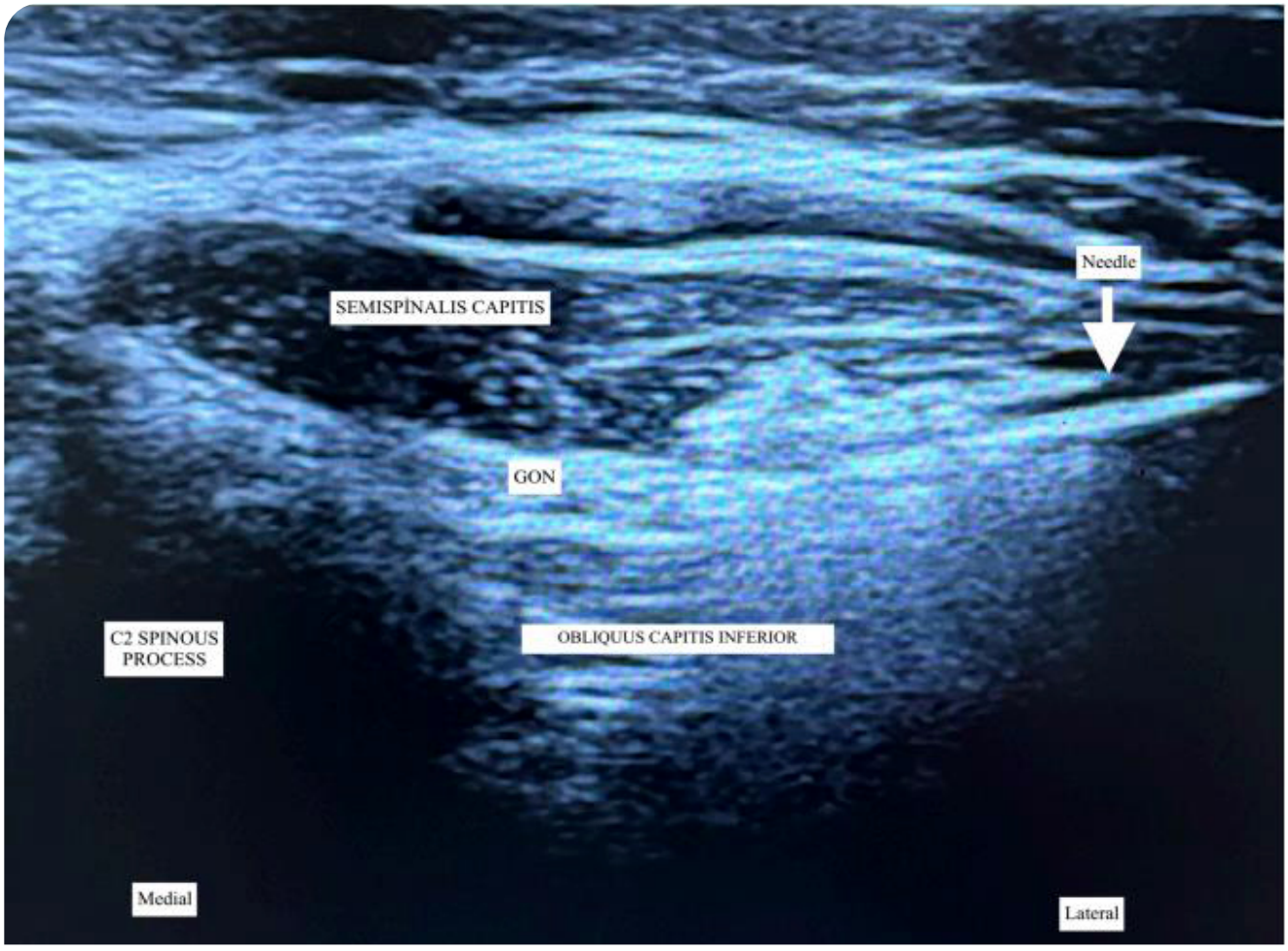

Figure 1. Representative ultrasound image demonstrating the proximal C2 approach for greater occipital nerve block. The C2 spinous process, obliquus capitis inferior, semispinalis capitis, greater occipital nerve (GON), and in-plane needle trajectory are shown.

Turk J Clin Res. 2026;2(1):22-30
https://doi.org/10.63909/1453040

Statistical Analysis

Data were analyzed using IBM SPSS Statistics for Windows, version 27.0 (IBM Corp., Armonk, NY, USA). Normality of continuous variables was assessed using the Shapiro–Wilk test. Descriptive data were expressed as mean ± standard deviation or median (interquartile range [IQR]), as appropriate, for continuous or ordinal variables, and as number (n) and percentage (%) for categorical variables. Repeated non-normally distributed or ordinal variables were compared using the Friedman test, followed by post hoc pairwise comparisons with Bonferroni correction when appropriate. Repeated binary categorical outcomes were analyzed using Cochran's Q test. For repeated categorical analysis of the Likert scale, treatment success was defined as a score of 2. A two-sided p value < 0.05 was considered statistically significant.

RESULTS

Baseline demographic and clinical characteristics of the patients are presented in Table 1. The mean age of the patients was 42.7±11.7 years, and 68.3% were female. The median duration of chronic migraine was 10.0 years (interquartile range, 15.0). Medication overuse headache was present in 68.3% of the patients. Bilateral block was performed in 80.5% of the patients.

Table 1. Baseline demographic and clinical characteristics of the patients (n = 41)

	Mean±standard deviation or Median (IQR)
Age	42.7±11.7
Sex (n/%)	
Female	28 (68.3)
Male	13 (31.7)
BMI	26.0±4.4
Weight status (n/%)	
Normal	16 (39.0)
Overweight	19 (46.3)
Obese	6 (14.6)
Duration of chronic migraine (years)	10.0 (15.0)
Aura n (%)	21 (51.2)
Medication overuse headache n (%)	28 (68.3)
Botulinum toxin type A injection history n (%)	7 (17.1)
Failure of prophylactic treatment n (%)	37 (90.2)
Depression/ Anxiety disorder n (%)	6 (14.6)
Sleep disorder n (%)	34 (82.9)
Fibromyalgia n (%)	17 (41.5)
Unilateral/Bilateral block n (%)	
Unilateral	8 (19.5)
Bilateral	33 (80.5)

Data are presented as mean ± standard deviation, median (interquartile range), or number (%), as appropriate. BMI: body mass index.

Table 2 presents changes in clinical variables and VAS scores at baseline and during follow-up after GON block. The number of headache days per month was lower at the 1st and 3rd months than before treatment (p<0.001), with no significant difference between the 1st and 3rd months (p=0.377). The number of headache days per month with VAS > 5 was lower at the 1st and 3rd months compared with before treatment (p<0.001), with no

Table 2. Changes in clinical variables and VAS scores at baseline and during follow-up after GON block

Variables	Before treatment	1st week	1st month	3rd month	P*	χ^2
Number of headache days per month	20.0 (6.0)	–	6.0 (5.0)	8.0 (7.0)	<0.001	70.5
P-value**			<0.001	<0.001		
Number of headache days per month with VAS > 5	12.0 (5.0)	–	4.0 (3.0)	4.0 (4.0)	<0.001	71.9
P-value** (Compared to baseline)			<0.001	<0.001		
VAS score	8.0 (4.0)	5.0 (2.0)	3.0 (3.0)	3.0 (2.0)	<0.001	96.4
P-value**		<0.001	<0.001	<0.001		
Attack duration, hours	12.0 (16.0)	–	5.0 (8.0)	4.0 (8.0)	<0.001	62.9
P-value**			<0.001	<0.001		

*Data are presented as median (interquartile range). *p values indicate overall changes over time and were analyzed using the Friedman test. **p values indicate pairwise comparisons with Bonferroni adjustment after Friedman analysis. χ^2 values represent Friedman test statistics.*

Turk J Clin Res. 2026;2(1):22-30
https://doi.org/10.63909/1453040

significant differences among the 1st week, 1st month, and 3rd month follow-up measurements (p>0.05). Attack duration was shorter at the 1st and 3rd months than before treatment (p<0.001), with no significant difference between the 1st and 3rd months (p=0.502).

GPE scores were not significantly different during follow-up (p=0.059). The HIT-6 score was lower at the 1st and 3rd months compared with baseline (both p < 0.001), while the scores at the 1st and 3rd months were similar (p=1.000). HIT-6 scores during follow-up are shown in Fig. 2. GPE and HIT-6 scores are presented in Table 3.

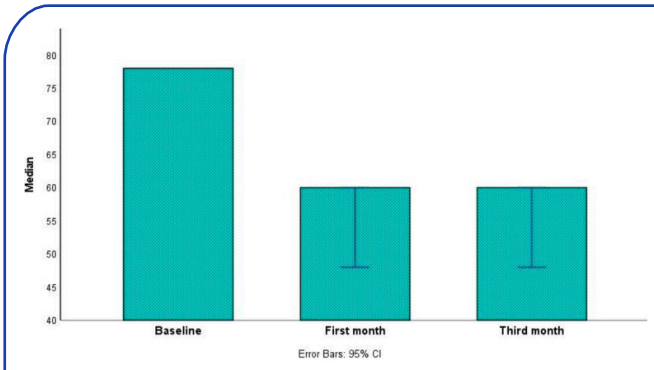

Figure 2. Changes in HIT-6 scores during follow-up.

Table 3.	Patient-reported outcomes across follow-up visits					
Variable	Before treatment	1st week	1st month	3rd month	P*	χ^2
GPE score	-	5.0 (1.0)	6.0 (2.0)	5.0 (2.0)	0.059	5.66
HIT-6 score	78.0 (0.0)	-	60.0 (12.0)	60.0 (12.0)	<0.001	69.1
p value**	-	-	<0.001	<0.001	-	-

Values are presented as median (interquartile range).
**P-values indicate overall changes over time analyzed using the Friedman test.*
***P-values indicate post hoc comparisons versus baseline with Bonferroni adjustment after the Friedman test.*
χ^2 values represent Friedman test statistics.
GPE: global perceived effect; HIT-6: Headache Impact Test-6.

Likert score distributions are presented in Table 4. When a Likert score of 2 was accepted as treatment success, the success rate increased significantly across follow-up visits (Cochran's Q test, p<0.001), from 7.3% at the 1st week to 19.5% at the 1st month and 36.6% at the 3rd month. No major procedure-related complications were observed during the study period.

Table 4.	Distribution of Likert scores across follow-up visits			
Variable	1st week n (%)	1st month n (%)	3rd month n (%)	p*
Likert Scale <0.001***				
0	12 (29.3)	16 (39.0)	10 (24.4)	
1	26 (63.4)	17 (41.5)	16 (39.0)	
2	3 (7.3)	8 (19.5)	15 (36.6)	

Values are presented as number (%).
P-value was calculated using * Cochran's Q test, with a Likert score of 2 accepted as treatment success.*

DISCUSSION

In this retrospective cohort of patients with chronic migraine, ultrasound-guided proximal C2 greater occipital nerve (GON) block was associated with rapid and sustained improvement across multiple clinically relevant outcomes during the 3-month follow-up period. Pain intensity improved as early as the first week and remained significantly lower at both the first and third months. In addition, monthly headache days, monthly severe headache days (VAS > 5), and attack duration were significantly reduced during follow-up. Headache-related disability also improved, as reflected by significantly lower HIT-6 scores at the first and third months. Although GPE scores did not differ significantly across visits, the proportion of patients achieving the predefined treatment success threshold increased over time. Overall, these findings suggest that ultrasound-guided proximal C2 GON blockade provides meaningful short- to intermediate-term clinical benefit in chronic migraine.

Greater occipital nerve block is considered a practical and valuable therapeutic option because of its ability to provide early pain relief, its relative technical simplicity, and its minimally invasive nature. The procedure is generally associated with a low incidence of adverse effects and drug interactions, and it represents a cost-effective intervention in the management of headache disorders. Several studies have suggested that ultrasound-guided techniques may enhance the clinical effectiveness of GON blockade compared with landmark-based approaches (13). Because of the functional interplay between occipital sensory pathways and the trigeminal nociceptive system, greater occipital nerve blockade is regarded as a useful therapeutic option for

Turk J Clin Res. 2026;2(1):22-30
https://doi.org/10.63909/1453040

reducing headache intensity and frequency in patients with migraine who do not respond adequately to medical therapy or cannot tolerate prophylactic treatment due to adverse effects (10,14). Consistent with this rationale, our findings support the short-term clinical utility of ultrasound-guided proximal C2 GON blockade in chronic migraine.

The greater occipital nerve (GON) arises primarily from the medial branch of the dorsal ramus of the second cervical spinal nerve (C2), with possible contributions from C3. It ascends between the obliquus capitis inferior and semispinalis capitis muscles and provides sensory innervation to the posterior scalp (15,16). Ultrasound-guided GON block can be performed using either a proximal or distal approach. In the proximal technique, the C2 spinous process is identified, and the transducer is moved laterally to visualize the nerve at the level of the obliquus capitis inferior muscle (17). In the distal approach, the occipital artery may serve as an anatomical landmark for needle placement (18).

The proximal technique for greater occipital nerve block, first described by Greher et al. in 2010, has been proposed as a more precise alternative to the traditional distal approach. At the level of the C2 vertebra, the GON is located within well-defined intermuscular planes, providing distinct sonographic characteristics. This anatomical configuration facilitates clearer ultrasound visualization and may allow the use of smaller volumes of local anesthetic. In addition, targeting the nerve at this proximal site may reduce unintended spread of injectate to adjacent structures, such as the lesser and third occipital nerves, thereby potentially enhancing procedural accuracy and safety (8). This proximal C2 approach was also the technique used in the present study.

A prior comparative study of ultrasound-guided proximal and distal GON block techniques reported that both approaches provided short-term improvements in headache severity, headache frequency, and sleep quality in patients with chronic migraine. Importantly, the proximal technique was associated with a longer duration of analgesic effect compared with the distal approach (17). From an anatomical and procedural perspective, targeting the nerve at the C2 level may offer distinct advantages, as the GON lies within clearly defined intermuscular planes that may enhance needle precision and reduce unintended spread of local anesthetic to adjacent neural or vascular structures. The deeper localization of the nerve may also reduce the risk of occipital artery injury. In addition, because the injection site is located away from the hair-bearing scalp, skin preparation and maintenance of sterile conditions may be facilitated. Both ultrasound-guided and landmark-based GON block techniques have been reported to be effective in the management of various headache disorders (19).

A comprehensive review evaluating the role of GON blockade across different headache syndromes concluded that the intervention provides clinical benefit in migraine, cluster headache, cervicogenic headache, post-dural puncture headache, and occipital neuralgia. The authors further noted that the strength of evidence appears more robust for acute and short-term symptom relief than for sustained long-term preventive effects (14). This is consistent with the short-term follow-up design of this study.

The effectiveness of greater occipital nerve block in chronic migraine has been demonstrated in several randomized controlled trials. The first randomized, multicenter, double-blind, placebo-controlled study by Inan et al. showed that repeated GON blocks with bupivacaine were superior to placebo and constituted a safe and effective treatment option (20). Similarly, another randomized controlled trial reported that lidocaine-based GON blocks administered over four weeks significantly reduced the number of painful days during a 12-week follow-up period (21).

Consistent with these findings, most randomized controlled trials have reported at least partial clinical benefit associated with GON blockade, supporting its role in both acute symptom relief and short-term preventive management of migraine (22). In line with this evidence, we observed significant reductions in monthly headache days and in the number of days with headache severity > 5 during the 3-month follow-up period.

In addition to randomized trials, observational and comparative studies further support the clinical utility of this intervention. Palamar et al. demonstrated that ultrasound-guided distal GON block with 0.5%

Turk J Clin Res. 2026;2(1):22-30
https://doi.org/10.63909/1453040

bupivacaine resulted in significant improvements in VAS scores and headache severity (23). Kissoon et al. reported superior pain relief with the proximal technique compared with the distal approach, particularly when ultrasound guidance was used (24). Similarly, Karaoğlan et al. found that C2-level GON blockade was effective at three months, although bilateral applications did not show superiority over unilateral injections (25). These findings are consistent with the clinical improvements observed in our cohort.

In a recent prospective comparative cohort study, Dadali et al. reported that ultrasound-guided proximal C2 greater occipital nerve pulsed radiofrequency resulted in more sustained reductions in headache duration, attack frequency, headache days, and VAS scores compared with repeated GON blocks over a three-month follow-up period. Importantly, both interventions were associated with only mild and transient adverse effects, supporting the favorable safety profile of proximal image-guided GON procedures (26). This is also in line with our observations, as no major procedure-related complications were encountered.

LIMITATIONS

This study has several limitations. First, its retrospective, single-center design and the absence of a control or placebo group limit causal inference and preclude definitive conclusions regarding comparative efficacy. Second, the sample size was relatively small, which may have reduced the power to detect changes in some patient-reported outcomes, particularly GPE. Third, the 3-month follow-up period does not allow assessment of long-term durability or the need for repeated procedures over time. Fourth, because only the ultrasound-guided proximal C2 technique was evaluated, direct comparisons with distal or landmark-based approaches were not possible. Finally, the study population included a clinically complex chronic migraine cohort with a high rate of medication overuse headache, which may enhance real-world applicability but may also limit generalizability to other migraine populations. Larger prospective controlled studies with longer follow-up are needed to confirm these findings and better define the optimal role of ultrasound-guided proximal C2 GON blockade in chronic migraine.

CONCLUSION

Ultrasound-guided proximal C2 greater occipital nerve block appears to be a safe and clinically useful short-term treatment option in patients with chronic migraine. In this study, the procedure was associated with significant improvements in pain intensity, headache frequency, severe headache days, attack duration, and headache-related disability during the 3-month follow-up period. These findings support the potential role of anatomically precise, image-guided proximal GON blockade as a minimally invasive therapeutic approach in chronic migraine, although larger controlled studies with longer follow-up are needed to confirm its long-term efficacy and optimal positioning in clinical practice.

Acknowledgement: None.

Ethical Approval: The study was approved by the Giresun Training and Research Hospital Ethics Committee (decision no: 06, date: 04 March 2026).

Author Contributions: Idea/Concept: E.B., N.S.B.; Design: E.B.; Supervision: E.B.; Resources: E.B.; Materials: E.B.; Data Collection and/or Processing: E.B.; Analysis and/or Interpretation: E.B., N.S.B.; Literature Review: E.B., N.S.B.; Written by: E.B.; Critical Review: E.B., N.S.B.

Conflict of Interest: The authors declare that there is no conflict of interest.

Financial Disclosure: The authors declare that they received no financial support for this study.

REFERENCES

1. Waliszewska-Prosół M, Montisano DA, Antolak M, Bighiani F, Cammarota F, Cetta I, et al. The impact of primary headaches on disability outcomes: a literature review and meta-analysis to inform future iterations of the Global Burden of Disease study. J Headache Pain. 2024;25(1):27.
2. Headache Classification Committee of the International Headache Society. The International Classification of Headache Disorders, 3rd edition. Cephalalgia. 2018;38(1):1-211.
3. Buse DC, Greisman JD, Baigi K, Lipton RB. Migraine progression: a systematic review. Headache. 2019;59(3):306-38.

Turk J Clin Res. 2026;2(1):22-30
https://doi.org/10.63909/1453040

4. Young NP, Philpot LM, Vierkant RA, Rosedahl JK, Upadhyaya SG, Harris A, et al. Episodic and chronic migraine in primary care. Headache. 2019;59(7):1042-51.
5. Ashina S, Terwindt GM, Steiner TJ, Lee MJ, Porreca F, Tassorelli C, et al. Medication overuse headache. Nat Rev Dis Primers. 2023;9(1):5.
6. Raggi A, Leonardi M, Arruda M, Caponnetto V, Castaldo M, Coppola G, et al. Hallmarks of primary headache: part 1 - migraine. J Headache Pain. 2024;25(1):189.
7. Tubbs RS, Watanabe K, Loukas M, Cohen-Gadol AA. The intramuscular course of the greater occipital nerve: novel findings with potential implications for operative interventions and occipital neuralgia. Surg Neurol Int. 2014;5:155.
8. Greher M, Moriggl B, Curatolo M, Kirchmair L, Eichenberger U. Sonographic visualization and ultrasound-guided blockade of the greater occipital nerve: a comparison of two selective techniques confirmed by anatomical dissection. Br J Anaesth. 2010;104(5):637-42.
9. Bartsch T, Goadsby PJ. The trigeminocervical complex and migraine: current concepts and synthesis. Curr Pain Headache Rep. 2003;7(5):371-76.
10. Velásquez-Rimachi V, Chachaima-Mar J, Cárdenas-Baltazar EC, Loayza-Vidalon A, Morán-Mariños C, Pacheco-Barrios K, et al. Greater occipital nerve block for chronic migraine patients: a meta-analysis. Acta Neurol Scand. 2022;146(2):101-14.
11. Weibelt S, Andress-Rothrock D, King W, Rothrock J. Suboccipital nerve blocks for suppression of chronic migraine: safety, efficacy, and predictors of outcome. Headache. 2010;50(6):1041-4.
12. Shim JH, Ko SY, Bang MR, Jeon WJ, Cho SY, Yeom JH, et al. Ultrasound-guided greater occipital nerve block for patients with occipital headache and short-term follow-up. Korean J Anesthesiol. 2011;61(1):50-4.
13. Afridi SK, Shields KG, Bhola R, Goadsby PJ. Greater occipital nerve injection in primary headache syndromes: prolonged effects from a single injection. Pain. 2006;122(1-2):126-9.
14. Chowdhury D, Datta D, Mundra A. Role of greater occipital nerve block in headache disorders: a narrative review. Neurol India. 2021;69 Suppl:S228-S256.
15. Loukas M, El-Sedfy A, Tubbs RS, Louis RG Jr, Wartmann CH, Curry B, et al. Identification of greater occipital nerve landmarks for the treatment of occipital neuralgia. Folia Morphol (Warsz). 2006;65(4):337-42.
16. Mosser SW, Guyuron B, Janis JE, Rohrich RJ. The anatomy of the greater occipital nerve: implications for the etiology of migraine headaches. Plast Reconstr Surg. 2004;113(2):693-697; discussion 698-700.
17. Flamer D, Alakkad H, Soneji N, Tumber P, Peng P, Kara J, et al. Comparison of two ultrasound-guided techniques for greater occipital nerve injections in chronic migraine: a double-blind, randomized, controlled trial. Reg Anesth Pain Med. 2019;44(5):595-603.
18. Vanderhoek MD, Hoang HT, Goff B. Ultrasound-guided greater occipital nerve blocks and pulsed radiofrequency ablation for diagnosis and treatment of occipital neuralgia. Anesth Pain Med. 2013;3(2):256-9.
19. Ashkenazi A, Levin M. Greater occipital nerve block for migraine and other headaches: is it useful? Curr Pain Headache Rep. 2007;11(3):231-5.
20. Inan LE, Inan N, Karadaş Ö, Gül HL, Erdemoğlu AK, Türkel Y, et al. Greater occipital nerve blockade for the treatment of chronic migraine: a randomized, multicenter, double-blind, and placebo-controlled study. Acta Neurol Scand. 2015;132(4):270-7.
21. Chowdhury D, Tomar A, Deorari V, Duggal A, Krishnan A, Koul A. Greater occipital nerve blockade for the preventive treatment of chronic migraine: a randomized double-blind placebo-controlled study. Cephalalgia. 2023;43(2):3331024221143541.
22. Stern JI, Chiang CC, Kissoon NR, Robertson CE. Narrative review of peripheral nerve blocks for the management of headache. Headache. 2022;62(9):1077-92.
23. Palamar D, Uluduz D, Saip S, Erden G, Unalan H, Akarirmak U. Ultrasound-guided greater occipital nerve block: an efficient technique in chronic refractory migraine without aura? Pain Physician. 2015;18(2):153-62.
24. Kissoon NR, O'Brien TG, Bendel MA, Eldrige JS, Hagedorn JM, Mauck WD, et al. Comparative effectiveness of landmark-guided greater occipital nerve block at the superior nuchal line versus ultrasound-guided greater occipital nerve block at the level of C2: a randomized clinical trial. Clin J Pain. 2022;38(4):271-8.
25. Karaoğlan M, Durmuş İE, Küçükçay B, Takmaz SA, İnan LE. Comparison of the clinical efficacy of bilateral and unilateral GON blockade at the C2 level in chronic migraine. Neurol Sci. 2022;43(5):3297-303.
26. Dadali S, Babaoglu G, Sabuncu U, Akcaboy EY. Comparison of the efficacy of ultrasound-guided repeated greater occipital nerve blocks and greater occipital nerve pulsed radiofrequency in migraine treatment. Pain Physician. 2025;28(4):337-46.