Turkish Journal of Clinical Research

Turk J Clin Res. 2026;2(2):196-201
https://doi.org/10.63909/1453059

CASE REPORT

Multidisciplinary management of avulsed maxillary incisors during orthodontic treatment: A case report

Ortodontik tedavi sırasında avülse olan maksiller kesici dişlerin multidisipliner yönetimi: Bir olgu sunumu

Metin Berk KASAPOGLU[1], Gulce Ecem DOGANCALI[1], Berkan DUMAN[2], Deniz TURGUT[3], Selahattin Cem UNSAL[4], Ahmet Taylan CEBI[5], Mehmet Ali ERDEM[1]

[1]İstanbul University, Faculty of Dentistry, Department of Oral and Maxillofacial Surgery, İstanbul, Türkiye
[2]İstanbul University, Institute of Graduate Studies in Health Sciences, Department of Oral and Maxillofacial Diseases and Surgery, İstanbul, Türkiye
[3]İstanbul University, Faculty of Dentistry, Department of Endodontics, İstanbul, Türkiye
[4]İstanbul University, Faculty of Dentistry, Department of Orthodontics, İstanbul, Türkiye
[5]Karabük University, Faculty of Dentistry, Department of Oral and Maxillofacial Surgery, Karabük, Türkiye

Abstract

Traumatic avulsion of multiple permanent incisors during active orthodontic treatment is rare. We report the case of an adolescent who experienced simultaneous avulsion of three maxillary incisors while wearing fixed orthodontic appliances. Notably, the avulsed teeth remained attached to the orthodontic archwire via their brackets, thereby staying in a salivary environment until replantation. The patient was referred within two hours of the trauma, and the teeth were replanted and stabilized with a semi-rigid splint, minimizing the extra-alveolar dry time. Root canal treatment was initiated on day 9, including calcium hydroxide medication to prevent inflammatory resorption. At the three-year follow-up, all teeth remained functional and stable, with only mild external root resorption. This case highlights the importance of prompt multidisciplinary management and demonstrates that preserving natural teeth can maintain aesthetics, function, and psychosocial well-being.

Keywords: Dental avulsion, endodontic treatment, external root resorption, replantation, dental trauma management.

Özet

Ortodontik tedavi sırasında çoklu daimi kesici diş avülsiyonu nadir görülen bir klinik durumdur. Bu olguda, sabit ortodontik tedavi görmekte olan genç erkek bir hastada üç maksiller kesici dişin eş zamanlı avülsiyonu ve tedavi süreci sunulmaktadır. Olgunun dikkat çekici yönü, avülse dişlerin braketleri aracılığıyla ortodontik ark teline bağlı kalarak replantasyona kadar ağız içinde, tükürük ortamında kalmış olmasıdır. Hasta travmadan sonraki iki saat içerisinde kliniğe başvurmuş, dişler replante edilerek rijit splintle stabilize edilmiştir; böylece ekstra-alveoler kuru süre minimal düzeyde tutulmuştur. Kök kanal tedavisine 9. günde başlanmış ve inflamatuvar kök rezorpsiyonunu önlemek amacıyla kalsiyum hidroksit medikasyonu uygulanmıştır. Üç yıllık takipte, dişlerin fonksiyonel ve stabil olduğu, radyografik olarak yalnızca hafif derecede eksternal kök rezorpsiyonu izlendiği belirlenmiştir. Bu olgu, zamanında gerçekleştirilen multidisipliner yaklaşımın önemini ortaya koymakta ve doğal dişlerin korunmasının estetik, fonksiyonel ve psikososyal açıdan sağladığı katkıyı vurgulamaktadır.

Anahtar Kelimeler: Diş avülsiyonu, endodontik tedavi, eksternal kök rezorpsiyonu, replantasyon, dental travma yönetimi.

INTRODUCTION

Dentoalveolar trauma is a significant injury commonly observed among children and young adults and requires timely and appropriate dental intervention (1). Falls are the leading cause, followed by sports-related injuries (2). Avulsion, defined as the complete displacement of a tooth from its alveolar socket, accounts for 0.5–16% of dental traumatic injuries and most frequently involves the maxillary central incisors due to their prominent position in the dental arch (1,3).

The consequences of dental avulsion vary among individuals and may affect quality of life, psychological and social well-being, and treatment costs (4). Although implant therapy is considered an ideal treatment option for adults, its use in adolescents remains controversial. Therefore, preserving traumatized teeth through endodontic treatment, particularly in young patients, provides significant functional, aesthetic, psychological, and bone-preservation benefits (5).

Corresponding Author: Berkan DUMAN dtberkanduman@gmail.com
Cite as: Kasapoglu MB, Dogancali GE, Duman B, Turgut D, Unsal SC, Cebi AT, et al. Multidisciplinary management of avulsed maxillary incisors during orthodontic treatment: A case report. Turk J Clin Res. 2026;2(2):196-201

Content of this journal is licensed under a Creative Commons Attribution-NonCommercial-NonDerivatives 4.0 International License

Received: 17 April 2026 | **Accepted:** 7 May 2026 | **Published:** 31 May 2026

Turk J Clin Res. 2026;2(2):196-201
https://doi.org/10.63909/1453059

Optimal management of dental avulsion requires immediate replantation to restore function and aesthetics. Success depends on root apex development and periodontal ligament (PDL) viability, both of which are influenced by extraoral time and storage conditions (1,6). Andreasen et al. identified 30 minutes as a critical period for optimal PDL healing; beyond this period, ligament damage should be assessed (7). An ideal storage medium should preserve PDL viability, support fibroblast repair, and maintain suitable pH, osmolarity, and nutrient conditions. Readily available natural storage media, such as coconut water, milk, and saliva, have been used alongside artificial solutions, including Viaspan and Hank's Balanced Salt Solution (8). Despite its low osmolarity and risk of bacterial contamination, saliva effectively prevents desiccation (9).

Root apex development is crucial in treatment decision-making. In teeth with open apices, delaying endodontic therapy supports revascularization, whereas teeth with closed apices require endodontic treatment within 2 weeks to prevent inflammatory root resorption. Post-avulsion infection and root resorption remain important risks that may compromise prognosis and long-term survival (10).

Traumatic dental injuries occurring during active orthodontic treatment require additional clinical consideration, as fixed appliances may affect both the pattern of injury and the emergency management process. Although orthodontic appliances may complicate acute trauma management, orthodontic archwires can, in selected circumstances, act as temporary retaining or stabilizing structures by helping maintain traumatized teeth within the intraoral environment until definitive treatment is provided (11).

Therefore, this case report describes the replantation of two central and one lateral maxillary incisors avulsed due to a fall in a young patient undergoing active orthodontic treatment, emphasizing the unexpected protective role of the orthodontic archwire, multidisciplinary management, and three-year follow-up findings.

CASE REPORT

A 16-year-old male patient presented to another emergency center following trauma to the anterior maxilla due to a fall. He was referred to Istanbul University, Faculty of Dentistry, Department of Oral and Maxillofacial Surgery approximately two hours after the trauma. Extraoral examination revealed edema and lacerations on both lips. Intraorally, avulsion of the maxillary right central incisor and the maxillary left central and lateral incisors was observed (Figure 1a). As the patient was undergoing orthodontic treatment, the avulsed teeth had remained attached to the orthodontic archwire via their brackets, thus staying in the intraoral salivary environment until arrival. Additionally, a mesial crown fracture was noted on the maxillary right central incisor.

After obtaining informed consent from the patient and his parents, the treatment process was initiated. First, the avulsed teeth were carefully separated from the orthodontic wires and preserved in cold milk. The soft tissue lacerations on the lips were repaired with sutures. To evaluate possible additional injuries to adjacent teeth and alveolar structures, an orthopantomograph (OPG) was obtained, which revealed no further trauma (Figure 1b). Following clinical and radiographic examinations, the patient and his family were thoroughly informed about possible complications after replantation, including root resorption, ankylosis, and infection risk, and treatment was continued accordingly.

Local anesthesia was administered using 2% lidocaine, and the tooth sockets were irrigated with povidone-iodine without disrupting clot integrity. The avulsed teeth, which had previously been stored in milk, were gently rinsed with saline and repositioned into their sockets. Semi-rigid splinting was achieved using a heat-treated 0.020-inch orthodontic retainer wire secured with flowable composite resin (Filtek™ Flow, 3M ESPE) and the total-etch technique, incorporating support from the adjacent teeth (Figure 1c). The patient was instructed to retain the splint for at least two weeks and was prescribed antibiotics, analgesics, and an antibacterial mouthwash. To facilitate healing, the patient was instructed to follow a soft diet, avoid applying force to the anterior teeth, and maintain optimal oral hygiene. As the trauma occurred on a marble floor, tetanus vaccination was deemed unnecessary.

Turk J Clin Res. 2026;2(2):196-201
https://doi.org/10.63909/1453059

The patient returned for follow-up two days later, presenting with erythema and localized swelling around the replanted teeth, which remained stable (Figure 1d). Pain was reported but was effectively managed with analgesics.

On day 9 after the trauma, root canal treatment was initiated for the maxillary right and left central incisors and the maxillary left lateral incisor. The teeth were isolated with a rubber dam using premolar clamps. A glide path was created with size 10 K-files, and the working lengths were measured electronically and confirmed radiographically. Chemomechanical preparation was performed using the step-back technique with K-files and sodium hypochlorite (NaOCl) irrigation. Calcium hydroxide was applied as an intracanal medicament to reduce the risk of resorption.

On day 28, calcium hydroxide was completely removed using NaOCl irrigation and ultrasonic activation (Ultra X, Eighteeth). The root canals were obturated with lateral condensation using Adseal (Meta Biomed), a gutta-percha and epoxy resin-based sealer. The access cavities were restored with composite resin (Filtek™ Z350 XT, 3M ESPE) (Figure 1e). After removal of the splint on day 30, the crown fracture of the maxillary right central incisor was restored with composite resin.

Radiographic evaluations were performed at 3, 6, 12, 24, and 36 months. At three months, the patient had no complaints, and clinical examination showed no signs of ankylosis or replacement resorption; vertical percussion produced no significant metallic sound. At one year, intraoral examination (Figure 2a) and panoramic radiography (Figure 2b) revealed no pathological changes. However, at two years, periapical radiographs and panoramic radiography (Figure 2c) showed superficial resorption in the apical regions of the maxillary left central and lateral incisors, along with mild external resorption apically and mesially in the maxillary right central incisor. At the three-year follow-up, intraoral examination (Figure 3a) and panoramic radiography (Figure 3b) revealed no changes in the extent of resorption. The patient remained asymptomatic, functionally stable, and aesthetically satisfied.

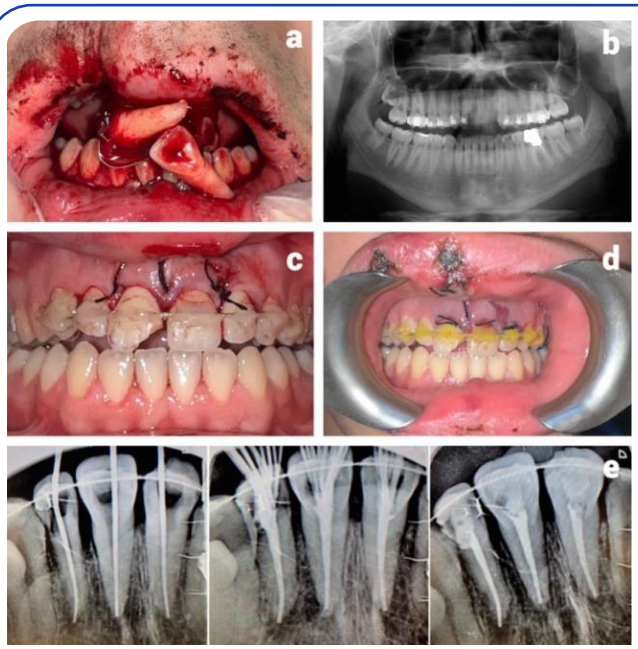

Figure 1. a. Initial intraoral clinical photograph of the patient; b. Initial panoramic radiograph of the patient; c. Intraoral clinical photograph of the patient after splint placement; d. Intraoral clinical photograph of the patient on day 2; e. Periapical radiographs illustrating the stages of endodontic treatment: master cone, lateral condensation, and final obturation

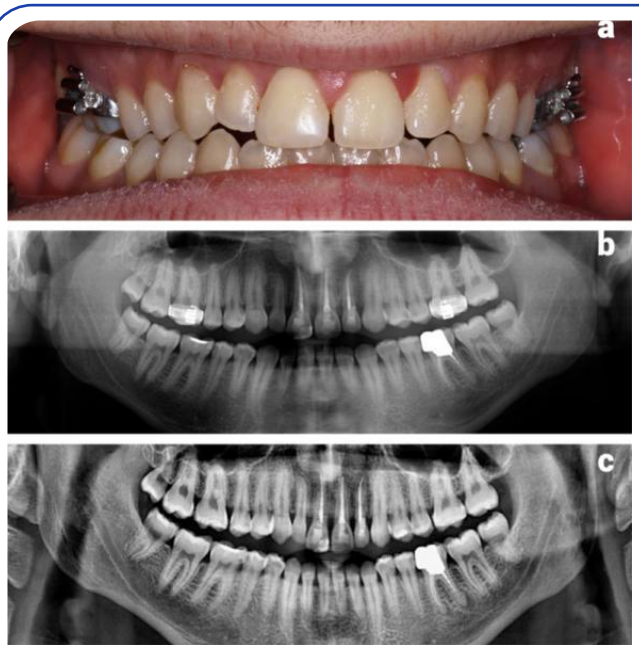

Figure 2. a. Intraoral clinical photograph of the patient at the one-year follow-up; b. Panoramic radiograph of the patient at the one-year follow-up; c. Panoramic radiograph of the patient at the two-year follow-up

Turk J Clin Res. 2026;2(2):196-201
https://doi.org/10.63909/1453059



Figure 3. a. Intraoral clinical photograph of the patient at the three-year follow-up; b. Panoramic radiograph of the patient at the three-year follow-up

DISCUSSION

Traumatic dental injuries constitute a substantial medical and economic burden, affecting more than one billion individuals globally (12). Proper management of dental trauma not only helps restore aesthetic and functional integrity but also significantly improves treatment prognosis by minimizing long-term complications.

Dental trauma predominantly affects the maxillary incisors due to their exposed anatomical position, whereas mandibular anterior teeth are less frequently involved because forces are dissipated through the temporomandibular joint (13). Additionally, such injuries have been reported to be more common in males due to behavioral factors (2), which is consistent with the present case.

To prevent inflammatory external root resorption in avulsed teeth with closed apices, root canal treatment should be initiated within two weeks after replantation (1). Two intracanal medicament protocols have been described. The first involves applying calcium hydroxide 7–10 days after replantation for two weeks, whereas the second includes the immediate or early use of an antibiotic-corticosteroid medicament for two weeks, followed by calcium hydroxide for an additional two weeks; however, the clinical efficacy of the latter remains inconclusive (14). In this case, root canal therapy was initiated nine days after replantation, and calcium hydroxide treatment was maintained for approximately three weeks, concluding on day 28.

In the literature, the risk of root resorption in replanted maxillary central incisors has been reported to vary considerably depending on several factors, including extraoral time, storage conditions, the timing and type of endodontic protocol, splint type and duration, and the use of adjunctive biomaterials (4). El Kharroubi et al. (15) stored the teeth in milk for 60 minutes, performed pulpectomy in the first week, applied calcium hydroxide therapy for three months, used flexible splinting for four weeks, and reported no resorption after a three-year follow-up. Gharechahi and Shojaeian (16) documented a case in which a tooth stored in saliva for four hours was replanted, with simultaneous revascularization of the contralateral central incisor, resulting in periapical healing after 18 months.

In the present case, external root resorption was identified only at the end of the second year, a finding that may be considered favorable given its delayed onset. This outcome is thought to be primarily related to the preservation of the teeth in the intraoral environment through their attachment to the orthodontic archwire, which likely contributed to maintaining periodontal ligament viability. However, the occurrence of resorption could not be entirely prevented, which may be attributed to certain factors. Specifically, the approximately two-hour extra-alveolar period, albeit in a salivary medium, represented a relatively prolonged duration, and the patient's inability to achieve complete lip closure due to soft tissue lacerations may have adversely affected the healing capacity of the periodontal ligament.

According to the International Association of Dental Traumatology (IADT) guidelines, replanted permanent teeth should generally be stabilized with a passive flexible splint for two weeks; however, longer stabilization may be required in cases requiring additional support, particularly when associated alveolar or periodontal injury compromises early stability (1). In the present case, the semi-rigid orthodontic wire-composite splint was maintained for 30 days because three adjacent

Turk J Clin Res. 2026;2(2):196-201
https://doi.org/10.63909/1453059

maxillary incisors had been avulsed simultaneously and additional stabilization was considered necessary during the early healing phase. This approach provided sufficient stabilization while allowing physiological mobility. Regular clinical and radiographic evaluations at two and four weeks, three months, six months, one year, and annually thereafter are essential for accurate prognosis (1). In this case, a three-year follow-up was completed with detailed documentation, and the patient remains under observation.

In young patients, preserving teeth within the oral cavity not only protects functional and aesthetic integrity but also provides substantial psychosocial benefits. In this case, contrary to the patient's initial expectation of tooth loss, successful preservation resulted in both aesthetic and functional satisfaction, thereby enhancing adherence to the treatment process. Moreover, in traumatic scenarios where oral and facial integrity is frequently compromised and dental management often becomes a secondary concern, this report highlights the pivotal role of timely and appropriate dental intervention. Particularly in young individuals, maintaining traumatized teeth through coordinated multidisciplinary care can significantly improve long-term prognosis and overall quality of life.

CONCLUSION

In conclusion, this case report demonstrates that prompt multidisciplinary management is essential for achieving favourable functional and aesthetic outcomes after the replantation of avulsed permanent teeth. The long-term prognosis of replantation depends on timely intervention, appropriate storage conditions, preservation of periodontal ligament viability, early endodontic treatment, suitable splinting, and regular follow-up. In the present case, the favourable three-year outcome was supported by early referral, extra-alveolar dry time minimization, calcium hydroxide medication, semi-rigid splinting, closed root apices, and the young age of the patient. The most distinctive aspect of this case is that the existing orthodontic archwire acted as an unplanned intraoral retaining structure, keeping the avulsed teeth within the salivary environment until replantation. This unexpected protective role may have helped prevent complete desiccation of the periodontal ligament and contributed to the maintenance of the teeth in a functional and aesthetically acceptable condition. Therefore, although fixed orthodontic appliances may complicate trauma management, they may also provide a potential advantage in selected avulsion cases by supporting intraoral preservation until definitive treatment is performed.

Acknowledgement: None.

Ethical Approval: Ethical approval was not required for this case report in accordance with institutional policies. Written informed consent was obtained from the patient and the patient's legal guardian for publication of this case and accompanying images.

Author Contributions: Idea/Concept: M.B.K., G.E.D., B.D.; Design: M.B.K.; Supervision: M.A.E.; Resources: D.T., S.C.U., A.T.C.; Materials: B.D., D.T., S.C.U.; Data Collection and/or Processing: G.E.D., B.D.; Analysis and/or Interpretation: M.B.K., A.T.C.; Literature Review: B.D.; Written by: B.D., D.T., S.C.U.; Critical Review: M.B.K., G.E.D., A.T.C.

Conflict of Interest: The authors declared no conflict of interest.

Financial Disclosure: The authors declared that this case report has received no specific grant from any funding agency in the public, commercial, or not-for-profit sectors.

REFERENCES

1. Fouad AF, Abbott PV, Tsilingaridis G, Cohenca N, Lauridsen E, Bourguignon C, et al. International Association of Dental Traumatology guidelines for the management of traumatic dental injuries: 2. Avulsion of permanent teeth. Dent Traumatol. 2020;36(4):331-42.
2. Juneja P, Kulkarni S, Raje S. Prevalence of traumatic dental injuries and their relation with predisposing factors among 8-15 years old school children of Indore city, India. Med Pharm Rep. 2018;91(3):328-35.
3. Singh M, Singh N, Dhiman RK, Kumar D. External replacement resorption in an avulsed reimplanted permanent incisors. J Int Clin Dent Res Organ. 2013;5(1):27-30.
4. Mazur M, Marasca R, Ottolenghi L, Vozza I, Covello F, Zupancich A, et al. Different resorptive patterns of two avulsed and replanted upper central incisors based on scanning electron microscopy and stereomicroscopic analysis: a case report. Appl Sci. 2020;10(10):3551.

Turk J Clin Res. 2026;2(2):196-201
https://doi.org/10.63909/1453059

5. Munoz-Sanchez ML, Decerle N, Devoize L, Nicolas E, Cousson PY, Veyrune JL, et al. Dental trauma management in a young teenager through endodontics and implantology: a case report. Healthcare (Basel). 2021;9(5):542.
6. Krastl G, Weiger R, Filippi A, Van Waes H, Ebeleseder K, Ree M, et al. Endodontic management of traumatized permanent teeth: a comprehensive review. Int Endod J. 2021;54(8):1221-45.
7. Andreasen JO, Andreasen FM, Tsilingaridis G. Avulsions. In: Andreasen JO, Andreasen FM, Andersson L, eds. Textbook and color atlas of traumatic injuries to the teeth. 5th ed. Hoboken (NJ): Wiley-Blackwell; 2018:486-528.
8. Ashkenazi M, Shaked I. In vitro clonogenic capacity of periodontal ligament fibroblasts cultured with Emdogain. Dent Traumatol. 2006;22(1):25-9.
9. Neha K, Kansal R, Garg P, Joshi R, Garg D, Grover HS. Management of immature teeth by dentin-pulp regeneration: a recent approach. Med Oral Patol Oral Cir Bucal. 2011;16(7):e997-e1004.
10. Souza BDM, Dutra KL, Kuntze MM, Bortoluzzi EA, Flores-Mir C, Reyes-Carmona J, et al. Incidence of root resorption after the replantation of avulsed teeth: a meta-analysis. J Endod. 2018;44(8):1216-27.
11. Patel K, Mack G, Djemal S. Management of acute traumatic dental injuries in the orthodontic patient. Br Dent J. 2022;232(10):695-700.
12. Petti S, Glendor U, Andersson L. World traumatic dental injury prevalence and incidence: a meta-analysis-one billion living people have had traumatic dental injuries. Dent Traumatol. 2018;34(2):71-86.
13. Patel MC, Sujan SG. The prevalence of traumatic dental injuries to permanent anterior teeth and its relation with predisposing risk factors among 8-13 years school children of Vadodara city: an epidemiological study. J Indian Soc Pedod Prev Dent. 2012;30(2):151-7.
14. Krastl G, Weiger R, Filippi A, Van Waes H, Ebeleseder K, Ree M, et al. European Society of Endodontology position statement: endodontic management of traumatized permanent teeth. Int Endod J. 2021;54(9):1473-81.
15. El Kharroubi S, Drouri S, Doumari B, Dhoum S, El Merini H. Management of 3 avulsed permanent teeth: case report of a 3-year follow-up. Case Rep Dent. 2022;2022:2081684.
16. Gharechahi M, Shojaeian S. Management of traumatized permanent incisors: revascularization and delayed replantation. N Y State Dent J. 2016;82(1):40-4.