Turkish Journal of Clinical Research

Turk J Clin Res. 2026;2(1):94-101
https://doi.org/10.63909/1453049

CASE REPORT

Pediatric fatal aluminum phosphide poisoning: A case report with management strategies

Pediatrik ölümcül alüminyum fosfit zehirlenmesi: Yönetim stratejileri ile bir olgu sunumu

Eren YILDIZ[1], Emrah CIGRI[1], Gizem KURADA[2], Busra TANYILDIZI KUCUK[3], Aysegul DOGAN[4], Hasim Yasin ERSAHIN[3], Ayse YILMAZ[5]

[1]Kastamonu University, Faculty of Medicine, Department of Pediatrics, Kastamonu, Türkiye
[2]Zonguldak Bülent Ecevit University, Faculty of Medicine, Department of Anesthesiology and Reanimation, Zonguldak, Türkiye
[3]Kastamonu University, Faculty of Medicine, Department of Anesthesiology and Reanimation, Kastamonu, Türkiye
[4]Samsun Gazi State Hospital, Department of General Intensive Care, Samsun, Türkiye
[5]İzmir Tınaztepe University, Faculty of Medicine, Department of Anesthesiology and Reanimation, İzmir, Türkiye

Abstract

Aluminum phosphide (AlP) is a highly lethal pesticide that releases phosphine gas upon contact with moisture, leading to marked impairment of mitochondrial function, severe oxidative stress, and multiorgan failure. A fifteen-year-old male patient was brought to the emergency department due to loss of consciousness following accidental ingestion of a tablet containing AlP. Severe metabolic acidosis and refractory cardiogenic shock developed within a short time; despite intensive fluid resuscitation, high-dose vasopressor support, and comprehensive treatment approaches including mechanical ventilation, hemodynamic stability could not be achieved, and the patient died due to progressive circulatory failure. The absence of a specific antidote makes the treatment of AlP poisoning extremely challenging and significantly limits management options, particularly in severe cases. In the literature, the pathophysiological mechanisms of phosphine toxicity have been described in detail, and vasopressor therapies in shock management, antioxidant approaches aimed at reducing oxidative injury, and extracorporeal membrane oxygenation (ECMO) as a potential rescue treatment option in refractory cardiogenic shock come to the forefront. This case is presented to highlight the clinical features and management challenges of fatal AlP poisoning.

Keywords: Aluminum phosphide poisoning, cardiogenic shock, multiorgan failure, refractory shock.

Özet

Alüminyum fosfit, nem ile temas ettiğinde fosfin gazı açığa çıkaran ve mitokondriyal fonksiyonda belirgin bozulmaya, şiddetli oksidatif strese ve çoklu organ yetmezliğine yol açan, yüksek derecede ölümcül bir pestisittir. On beş yaşında erkek bir hasta, alüminyum fosfit içeren bir tabletin kazara alınmasının ardından gelişen bilinç kaybı nedeniyle acil servise getirildi. Kısa süre içerisinde ağır metabolik asidoz ve dirençli kardiyojenik şok gelişti; yoğun sıvı resüsitasyonu, yüksek doz vazopresör desteği ve mekanik ventilasyonu da içeren kapsamlı tedavi yaklaşımlarına rağmen hemodinamik stabilite sağlanamadı ve hasta ilerleyici dolaşım yetmezliği nedeniyle kaybedildi. Spesifik bir antidotun bulunmaması, alüminyum fosfit zehirlenmesinin tedavisini son derece güçleştirmekte ve özellikle ağır olgularda yönetim seçeneklerini belirgin ölçüde sınırlamaktadır. Literatürde fosfin toksisitesinin patofizyolojik mekanizmaları ayrıntılı olarak tanımlanmış olup, şok yönetiminde vazopresör tedaviler, oksidatif hasarı azaltmayı amaçlayan antioksidan yaklaşımlar ve dirençli kardiyojenik şokta potansiyel bir kurtarıcı tedavi seçeneği olarak ekstrakorporeal membran oksijenasyonu (ECMO) ön plana çıkmaktadır. Bu olgu, ölümcül alüminyum fosfit zehirlenmesinin klinik özelliklerini ve yönetimindeki güçlükleri vurgulamak amacıyla sunulmuştur.

Anahtar Kelimeler: Alüminyum fosfit zehirlenmesi, kardiyojenik şok, çoklu organ yetmezliği, dirençli şok.

INTRODUCTION

Aluminum phosphide (AlP) is a highly toxic pesticide used as a fumigant and rodenticide in the storage of grains such as wheat and rice, particularly in developing countries, and is commonly known as the “wheat pill” or “rice tablet” (1). Even accidental or intentional oral ingestion of a small amount of AlP can be rapidly fatal; for example, ingestion of as little as 500 mg has been reported to result in mortality, demonstrating the extremely potent toxic effects of this agent (2). In the moist environment of the stomach, AlP undergoes hydrolysis and releases phosphine gas (3). Phosphine is a potent mitochondrial toxin that inhibits cytochrome c

Corresponding Author: Eren YILDIZ eren70@gmail.com
Cite as: Yildiz E, Cigri E, Kurada G, Kucuk Tanyildiz B, Dogan A, Ersahin HY, et al. Pediatric fatal aluminum phosphide poisoning: A case report with management strategies. Turk J Clin Res. 2026;2(1):94-101

Content of this journal is licensed under a Creative Commons Attribution-NonCommercial-NonDerivatives 4.0 International License

Received: 1 March 2026 | **Accepted:** 30 April 2026 | **Published:** 31 May 2026

Turk J Clin Res. 2026;2(1):94-101
https://doi.org/10.63909/1453049

oxidase and blocks oxidative phosphorylation, resulting in reduced cellular ATP production. In addition, phosphine generates reactive oxygen species (superoxide and peroxide radicals) that cause lipid peroxidation in cell membranes and glutathione depletion; this process leads to widespread cellular injury.

The cardiac and respiratory systems are the primary organ systems affected: acute toxic myocarditis and myocardial depression due to AlP toxicity lead to profound hypotension and cardiogenic shock, while pulmonary injury and the development of ARDS contribute to severe respiratory failure. Other organs such as the kidneys, liver, and brain may also be affected, manifesting as a multiorgan failure syndrome. In the absence of rapid and aggressive supportive therapy, death typically occurs due to circulatory collapse (shock).

There is no specific antidote for AlP poisoning, which makes treatment challenging. In this case report, we present a fatal acute AlP poisoning in an adolescent patient to illustrate the typical clinical course and to review current and emerging therapeutic strategies particularly the potential roles of vasopressor support, antioxidants, and ECMO in improving outcomes (3,4).

CASE PRESENTATION

A 15 year old male patient with no known medical history was brought to the emergency department by his family with complaints of altered consciousness, profuse vomiting, abdominal pain, dizziness, and sweating. According to witness statements, the patient had accidentally ingested a commercial grain preservative aluminum phosphide tablet containing approximately 3 grams of AlP about one hour before presentation, mistaking it for candy. At the onset of the event, it was unclear whether this was a suicide attempt or an intentional intoxication; the family reported that the tablet had been taken accidentally. Given suspected ingestion of a metal phosphide pesticide with potential phosphine off gassing, the patient was managed in a well ventilated resuscitation area, and contaminated materials (vomitus/clothing) were handled as potentially hazardous to minimize secondary exposure for healthcare personnel. At presentation, the patient opened his eyes to verbal stimuli, localized pain, but produced inappropriate speech; there was marked confusion. The Glasgow Coma Scale (GCS) score was assessed as 12 (E3 V4 M5).

The patient's vital signs were consistent with shock: blood pressure was 70/40 mmHg, and heart rate was 110 beats/min during the initial vital-sign assessment. The patient weighed approximately 60 kg; despite aggressive initial fluid resuscitation with three 500 mL isotonic saline boluses administered at 20 minute intervals, totaling 1500 mL, hypotension persisted. Respiratory rate was 30 breaths/min with shallow breathing, and oxygen saturation was 88% despite oxygen support via a reservoir mask at 15 L/min. A 12 lead ECG obtained shortly thereafter demonstrated a narrow complex rhythm at approximately 80 bpm with absent visible P waves and a notably short QT interval (Figure 1). The patient's skin was pale and moist; the extremities were cold, and peripheral pulses were weak. Cardiac auscultation revealed muffled heart sounds and an irregular rhythm accompanied by occasional ectopic beats.

Norepinephrine infusion was initiated at 0.15 mcg/kg/min, and epinephrine infusion at 0.05 mcg/kg/min. The patient's mental status rapidly deteriorated, with the GCS decreasing to 8 (E2 V2 M4), and he was intubated for airway protection.

Initial laboratory evaluation revealed creatinine 1.2 mg/dL and creatine kinase (CK) 323 U/L. At presentation, serum potassium was 3.5 mmol/L and glucose was 196 mg/dL. Other biochemical parameters were within normal limits (Table 1). Venous blood gas analysis showed pH 7.47, HCO_3 21 mmol/L, PCO_2 23.9 mmHg, base excess (BE) 5.6, and lactate 7.1 mmol/L. These values indicated significant tissue hypoxia. On repeat ECG, a regular narrow complex tachycardia at approximately 150 bpm was observed, accompanied by a relatively short QT interval and mild (<1 mm) ST-segment depression, predominantly in leads V2–V5 (Figure 2). Complete blood count revealed a hematocrit of 50% and leukocyte count of $15\times10^3/\mu L$; these findings were consistent with hemoconcentration and leukocytosis associated with hypovolemic shock.

At approximately 2 hours after emergency department arrival, repeat blood gas analysis showed pH 7.20, HCO_3 12 mmol/L, PCO_2 24 mmHg, BE 17, and lactate

Turk J Clin Res. 2026;2(1):94-101
https://doi.org/10.63909/1453049

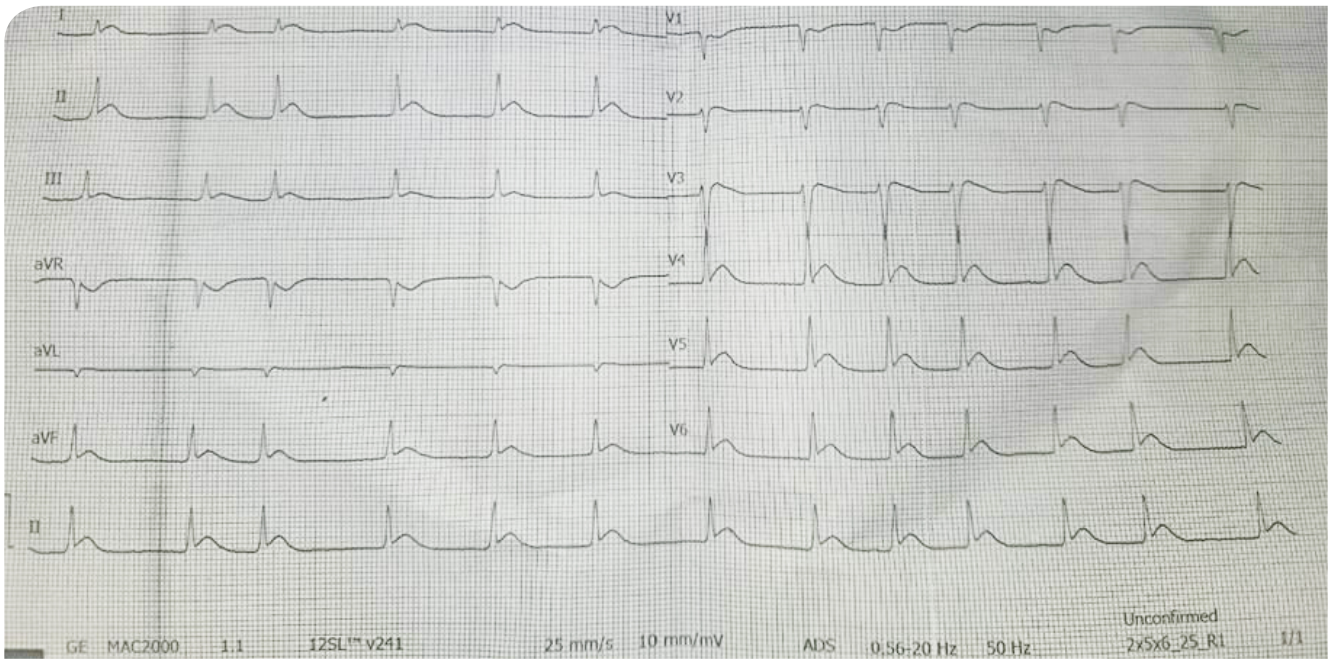

Figure 1. Initial 12-lead ECG demonstrating a narrow-complex rhythm (~80 bpm) with absent P waves

Table 1. Admission laboratory parameters

Biochemistry Panel			
Parameter	Result	Unit	Reference Range
Glucose	196	mg/dL	74–100
Urea	28	mg/dL	17–43
Creatinine	1.21	mg/dL	0.7–1.1
Sodium	139	mEq/L	136–146
Potassium	3.5	mEq/L	3.5–5.1
Chloride	106	mEq/L	100–109
Calcium	10.1	mg/dL	8.8–10.0
Magnesium	2.0	mg/dL	1.7–2.2
Total Bilirubin	0.6	mg/dL	0–1.0
ALT	17	U/L	0–24
AST	17	U/L	0–37
Alkaline Phosphatase	88	U/L	90–377
CK	323	U/L	0–170
CK-MB	17	U/L	0–25
CRP	1.2	mg/L	0–5
hs-Troponin I	<2	ng/L	0–20
Procalcitonin	<0.01	ng/mL	0–0.065

Hematology Panel			
Parameter	Result	Unit	Reference Range
WBC	14.72	10^3/µL	3.5–10
RBC	5.81	10^6/µL	4.3–5.7
Hemoglobin	17.3	g/dL	13.5–17.5
Hematocrit	50.0	%	40–54
MCV	84.3	fL	80–100
MCHC	35.3	g/dL	31–36
MCH	29.8	pg	27–34
RDW	11.9	%	11.5–15.5
Platelet	414	10^3/µL	150–450
Neutrophils#	6.46	10^3/µL	1.8–7.0
Lymphocytes#	6.63	10^3/µL	1.0–4.0
Monocytes#	1.24	10^3/µL	0.1–0.9
Eosinophils#	0.31	10^3/µL	0.02–0.5
Basophils#	0.08	10^3/µL	0–0.2

Turk J Clin Res. 2026;2(1):94-101
https://doi.org/10.63909/1453049

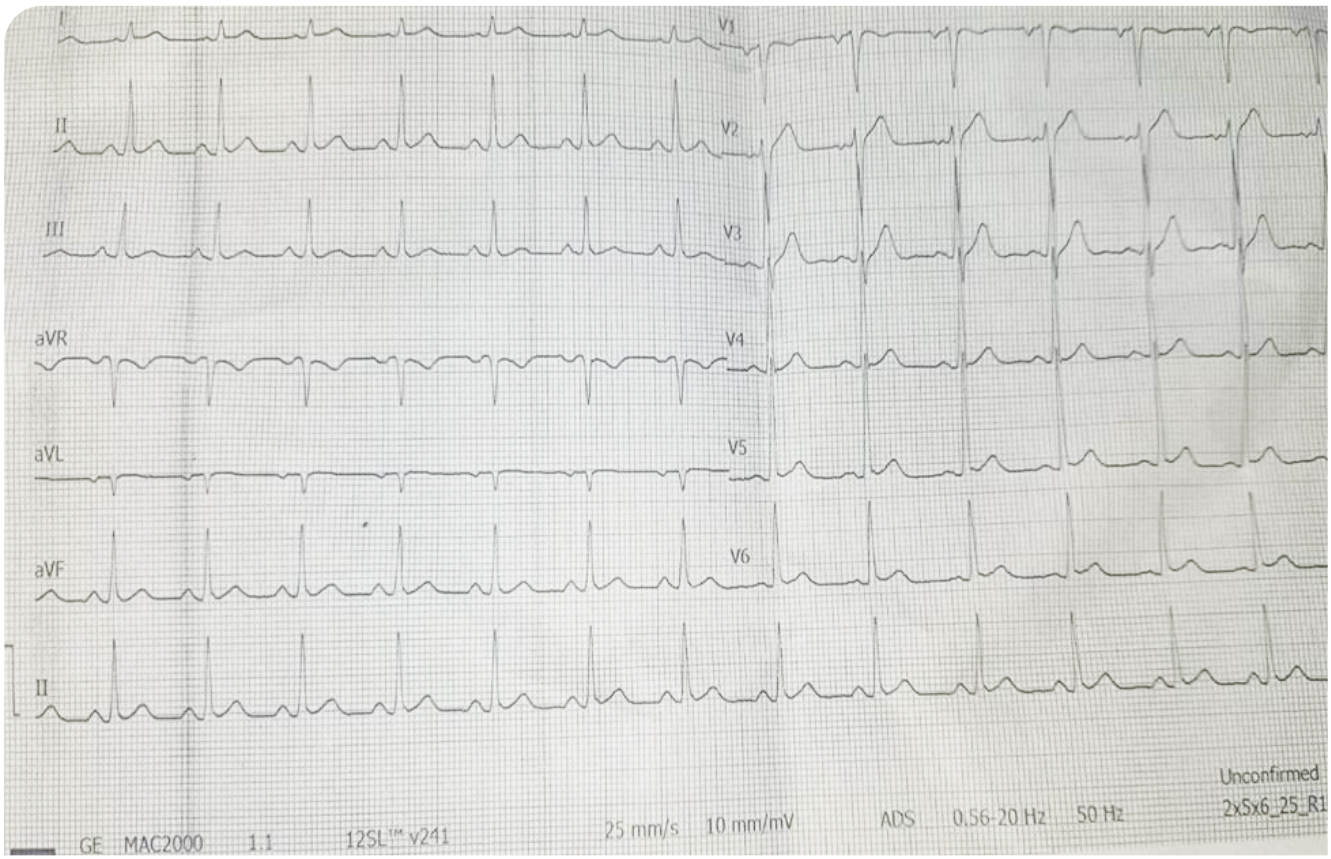

Figure 2. Follow-up ECG demonstrating narrow-complex tachycardia (~150 bpm) with ST-segment depression in leads V2–V5

10 mmol/L. These findings were consistent with severe metabolic acidosis. At the same time, serum potassium decreased to 2.6 mmol/L and bedside glucose was 50 mg/dL. Potassium chloride and dextrose treatments were initiated for hypokalemia and hypoglycemia.

In the second hour, the patient remained hypotensive, and the norepinephrine dose was increased to 1.5 mcg/kg/min and epinephrine to 0.3 mcg/kg/min. Due to refractory hypotension, dopamine infusion was started and titrated up to 20 mcg/kg/min according to hemodynamic response. During this period, mechanical ventilation with 100% oxygen was continued. Echocardiography revealed a dilated inferior vena cava with markedly reduced inspiratory collapsibility (<20%), suggesting worsening findings in favor of cardiogenic shock, and preparations for ECMO were initiated.

Despite inotropic and vasopressor therapies, the shock state did not improve, and veno arterial ECMO was planned. The pediatric intensive care unit team was consulted. However, before ECMO could be initiated, the patient developed cardiac arrest due to refractory cardiogenic shock. Cardiopulmonary resuscitation was commenced in the third hour of emergency department admission. Despite all interventions, return of spontaneous circulation could not be achieved, and the patient was pronounced dead approximately four hours after AlP ingestion.

DISCUSSION

Pathophysiology of AlP Poisoning

Aluminum phosphide (AlP) is a pro-toxin that releases phosphine gas (PH_3) upon contact with water or gastric acid, through which it exerts its toxic effects. The released phosphine is rapidly absorbed via inhalation or the gastrointestinal route (5). An important point is that phosphine, being rapidly oxidized in its gaseous form, cannot be persistently detected in blood or tissue samples. Therefore, diagnosis is generally based on the

Turk J Clin Res. 2026;2(1):94-101
https://doi.org/10.63909/1453049

clinical picture and on qualitative detection of phosphine in gastric contents or breath using methods such as the silver nitrate paper test (6,7).

Phosphine has multiple toxic effects. Primarily, it inhibits the mitochondrial enzyme cytochrome c oxidase, thereby halting the electron transport chain and blocking oxidative phosphorylation. This results in acute cellular energy failure and an inability to utilize oxygen (histotoxic hypoxia), which explains the severe lactic acidosis observed clinically (6).

Additionally, phosphine induces the production of reactive oxygen species (ROS), leading to significant oxidative stress. Consequently, lipid peroxidation in cell membranes increases, and denaturation of cellular proteins occurs. Depletion of intracellular glutathione stores further weakens the antioxidant defense system. In addition, electrolyte disturbances such as hypokalemia may occur in aluminum phosphide poisoning. Although the exact mechanism remains unclear, it is likely multifactorial, involving intracellular potassium shift due to catecholamine surge, gastrointestinal losses from profuse vomiting, and impaired cellular ion transport secondary to oxidative membrane damage (8). These mechanisms may explain the hypokalemia observed in our patient.

At the organ level, the heart is particularly vulnerable phosphine's direct cardiotoxic effect results in severe myocardial depression, arrhythmias, and acute heart failure. The combination of phosphine-induced widespread vasodilation and pump failure leads to circulatory collapse (i.e., simultaneous vasoplegic and cardiogenic shock) (9).

In the lungs, direct endothelial injury caused by inhaled phosphine or the secondary effects of shock and acidosis can lead to pulmonary edema and ARDS (7). Other reported effects of AlP/phosphine poisoning include acute kidney injury, hepatotoxicity, and disseminated intravascular coagulation (DIC); collectively, these contribute to multiorgan dysfunction (10).

Due to these pathophysiological mechanisms, death may occur within a few hours following AlP ingestion. Among survivors, permanent organ damage is frequently observed (5).

Supportive Therapy and Vasopressor Use

The treatment of AlP poisoning is entirely supportive; as no specific antidote exists, management focuses on maintaining vital functions until the toxin is eliminated from the body (5). One of the cornerstones of therapy is the provision of aggressive hemodynamic support. In severe cases of AlP poisoning, profound hypotension, myocardial depression, and widespread vasodilation result in a marked shock state (7).

Vasopressor agents are generally required to maintain perfusion. In clinical practice, norepinephrine is typically the first line pressor agent in AlP induced shock. In cases of refractory hypotension, combinations including epinephrine and vasopressin may be used. As in our case, the simultaneous use of multiple vasopressors is quite common. There is no consensus on the optimal vasopressor choice; treatment is tailored according to real time hemodynamic response.

Very high doses of vasopressors are often necessary; however, due to the severity of myocardial dysfunction, blood pressure may remain low despite these efforts. In addition to vasopressors, inotropic support (such as dobutamine or epinephrine, which also has inotropic properties) may be used to enhance myocardial contractility. Nonetheless, in situations where the myocardium is severely ischemic, excessive inotrope use must be approached cautiously, as it may precipitate fatal arrhythmias.

As demonstrated in our case, despite the use of multiple vasopressors and inotropes, the shock state often remains refractory, and unfortunately, this is a frequently encountered outcome in AlP poisoning (11). Ultimately, vasopressors are essential for sustaining life in AlP poisoning and often provide only a temporary solution. This underscores the need for more effective adjunctive therapeutic strategies (11).

Antioxidant and Adjunctive Therapies

Given the central role of oxidative injury in phosphine toxicity, various antioxidant agents have been investigated as adjunctive treatments. Magnesium sulfate is one of the best known supportive therapies in AlP poisoning. In addition to its antiarrhythmic effects,

Turk J Clin Res. 2026;2(1):94-101
https://doi.org/10.63909/1453049

magnesium serves as a cofactor for enzymes involved in intracellular glutathione regeneration. Low serum magnesium levels have frequently been reported in patients with AlP poisoning, and several studies have demonstrated that correcting magnesium deficiency may improve survival (12). In our case, magnesium levels were within the reference range; therefore, additional magnesium was not administered.

Other antioxidant therapies include N acetylcysteine (NAC) and Vitamin E. NAC replenishes intracellular glutathione and has been shown in animal studies on AlP poisoning to prolong survival time (13). Vitamin E, as a lipophilic antioxidant, interrupts the lipid peroxidation chain in cell membranes.

Clinical evidence regarding these antioxidants is steadily increasing. In a recent meta-analysis, the addition of antioxidants such as NAC, Vitamin E, Coenzyme Q10, and L-carnitine as complementary therapies was reported to improve survival in acute AlP poisoning (13). Coenzyme Q10 in particular, as a cofactor involved in mitochondrial function and energy production, has the potential to support myocardial function in AlP poisoning (14).

Experimental agents such as melatonin, which possesses strong antioxidant properties, have been shown in animal models to reduce cardiac injury and increase ATP production. Other adjunctive treatments include glucocorticoids (to reduce systemic inflammatory response and possible adrenal insufficiency), vasopressin (in vasodilatory shock), and digoxin (historically used in some cases to support cardiac output); however, none constitute definitive therapy (15).

It should be emphasized that no specific antidote exists that directly neutralizes phosphine. Therefore, antioxidants and adjunctive therapies aim primarily to mitigate damage and provide time for the body to eliminate the toxin (3).

Extracorporeal Membrane Oxygenation (ECMO) in AlP Poisoning

In recent years, ECMO has emerged as a critical rescue therapy in cases of severe cardiogenic shock caused by toxins, including AlP. Veno arterial ECMO (VA-ECMO) functions as a temporary artificial heart lung machine, providing circulatory and oxygenation support until the toxic effects resolve or cardiac function improves. Evidence supporting the use of ECMO in AlP poisoning has been steadily increasing.

A 2024 systematic review and meta-analysis by Moshiri et al. compared outcomes of AlP poisoning cases managed with ECMO versus conventional therapy. The analysis demonstrated that mortality was approximately 23% among patients who received ECMO, whereas it was around 60% in those who received only conventional intensive care ($p < 0.001$) (16).

In a large single-center study from India including 67 high risk AlP cases, the addition of VA-ECMO to standard treatment protocols was reported to reduce in-hospital mortality from 84.4% to 40% (17). Notably, patients who received ECMO presented in more severe condition initially (with lower ejection fraction and pH levels), yet exhibited significantly better survival compared with those who did not receive ECMO.

These findings indicate that ECMO may be life-saving in the most lethal phase of phosphine poisoning by temporarily supporting cardiac output. It is important to note that ECMO does not remove the toxin; rather, it prevents circulatory collapse the primary cause of death until recovery occurs. Due to significant resource requirements and risks of complications (e.g., bleeding, thrombosis, limb ischemia), ECMO is limited to selected patients who do not respond to conventional therapy and in whom cardiac function is expected to recover.

Successful cases of ECMO use in AlP poisoning have been reported in the literature. Because myocardial “stunning” commonly seen in AlP toxicity is often reversible, cardiac function may improve if the patient can be sustained long enough. Therefore, ECMO should be considered among the early treatment options for severe AlP poisoning (18-20).

In our case, ECMO was planned but could not be initiated due to the rapid clinical deterioration of the patient. This highlights how quickly AlP toxicity can progress in clinical practice. In some patients, cardiac arrest may occur before ECMO can be established. When feasible, the availability of ECMO should be assessed early. Early transfer of patients with refractory shock or severe

Turk J Clin Res. 2026;2(1):94-101
https://doi.org/10.63909/1453049

ventricular dysfunction to a center capable of providing ECMO is critical for improving survival.

OTHER CONSIDERATIONS

The presented case also highlights the public health and preventive aspects of the issue. Aluminum phosphide tablets are readily accessible in many agricultural regions; most poisoning incidents particularly among young individuals occur with suicidal intent. Preventive measures such as restricting access to AlP and educating at-risk communities are critically important in reducing the frequency of these poisonings.

From an intensive care management perspective, early consultation with a toxicologist or communication with a regional poison control center is recommended when AlP poisoning is suspected. Ultimately, the management of AlP poisoning requires a multidisciplinary approach. Despite all intensive therapeutic efforts, some cases may not be salvageable due to the lethal potential of the toxin. This underscores the urgent need for the development of specific antidotes or more effective treatments for phosphine poisoning.

CONCLUSION

Aluminum phosphide poisoning is an extremely lethal emergency with no specific antidote. The presented case clearly demonstrates the rapidly progressive clinical course that results in multiorgan failure and death shortly after ingestion. Clinicians should consider AlP poisoning particularly in patients from agricultural regions who present with refractory shock and metabolic acidosis, as early and aggressive treatment may be life-saving.

The fundamental principles of treatment include rapid gastrointestinal decontamination to reduce phosphine release, intensive circulatory support with fluids and vasopressors, correction of metabolic disturbances, and supportive interventions with antioxidant properties. In cases that develop refractory cardiogenic shock, ECMO emerges as a treatment option capable of significantly improving survival.

The implementation of ECMO requires appropriate infrastructure and expertise; however, its potential to reduce mortality in AlP poisoning represents a significant advancement in the management of this condition. The current literature suggests that a multimodal strategy combining intensive supportive therapy with innovative approaches such as vasopressors, antioxidant treatments, and ECMO offers the best chance of success in this frequently fatal poisoning.

Finally, preventive public health measures such as regulation of pesticide use and increasing community awareness are critically important in reducing the incidence of these high mortality poisonings. In particular, restricting retail access to aluminum phosphide preparations and ensuring safe storage/packaging to prevent adolescent and pediatric exposure should be prioritized. Further research is needed to develop targeted antidotes and optimize supportive treatment protocols for aluminum phosphide poisoning. The ultimate goal is to transform this often fatal poisoning into a more manageable and potentially survivable clinical condition.

Acknowledgement: None.

Ethical Approval: Ethical review and approval were waived for this study due to its nature as a single case report.

Author Contributions: Idea/Concept: E.Y., E.C.; Design: E.Y., G.K., A.D.; Supervision: H.Y.E., A.Y.; Resources: E.C., B.T.K.; Materials: G.K., B.T.K.; Data Collection and/or Processing: E.Y., G.K., B.T.K.; Analysis and/or Interpretation: E.C., A.D., H.Y.E.; Literature Review: E.Y., A.Y.; Written by: E.Y., E.C.; Critical Review: H.Y.E., A.Y.

Conflicts of Interest: The authors declare no conflict of interest.

Financial Disclosure: This research received no external funding.

REFERENCES

1. Rehman HU, Mansoor VB, Syed F, Arif MA, Javed A. Wheat pill poisoning: complications and management. J Pak Med Assoc. 2021;71(6):1676-8.
2. Sahoo D, Kujur ST, Das DS, Dey A, Devi S. Aluminium phosphide poisoning: early suspicion of cardiotoxicity is necessary for improved outcomes. Cureus. 2020;12(9):e10237.

Turk J Clin Res. 2026;2(1):94-101
https://doi.org/10.63909/1453049

3. Gurjar M, Baronia AK, Azim A, Sharma K. Managing aluminum phosphide poisonings. J Emerg Trauma Shock. 2011;4(3):378-84.
4. El-Sarnagawy GN, Hafez ASAF, Ghonem MM. Role of serum glucose/potassium ratio in assessing poisoning severity and adverse outcomes in patients with acute aluminum phosphide poisoning. Toxicol Rep. 2025;14:101947.
5. Katwal S, Malbul K, Mandal SK, Kc S, Alam MZ, Karki P, et al. Successfully managed aluminum phosphide poisoning: a case report. Ann Med Surg (Lond). 2021;70:102868.
6. Mehrpour O, Jafarzadeh M, Abdollahi M. A systematic review of aluminium phosphide poisoning. Arh Hig Rada Toksikol. 2012;63(1):61-73.
7. Hájek M, Chmelař D, Tlapák J, Rybárová V, Ondra P, Halouzka V. Accidental aluminum phosphide intoxication successfully treated with hyperbaric oxygen therapy: a case report. Toxics. 2024;12(4):272.
8. Hashemi-Domeneh B, Zamani N, Hassanian-Moghaddam H, Rahimi M, Shadnia S, Erfantalab P, et al. A review of aluminium phosphide poisoning and a flowchart to treat it. Arh Hig Rada Toksikol. 2016;67(3):183-93.
9. Ghonem MM, Abdelnoor AA, Hodeib AA. Shock and modified shock indices in predicting poisoning severity and outcomes in acute aluminum phosphide poisoned patients. Toxicol Res (Camb). 2023;13(1):tfad124.
10. Sarkar MK, Ghosh N, Rakesh U, Prasad R, Raj R. Acute aluminium phosphide poisoning: a case report of rare survival with cardiac, metabolic, hepatic, and renal complications. J Family Med Prim Care. 2022;11(11):7452-5.
11. Adel B, Elgharbawy NM, Shahin MM, Abo-Elfadl AA, Saad KM. Insulin-euglycemia therapy in acute aluminum phosphide poisoning: a randomized clinical trial. Clin Toxicol (Phila). 2023;61(12):1032-9.
12. Chugh SN, Kolley T, Kakkar R, Chugh K, Sharma A. A critical evaluation of anti-peroxidant effect of intravenous magnesium in acute aluminium phosphide poisoning. Magnes Res. 1997;10(3):225-30.
13. Ayele M, Ayenew KD. Update in the management of acute aluminum phosphide poisoning: a narrative review. WebLog J Toxicol. 2025;1:wjt.2025.j2901.
14. Elsharkawy RE, Ghonem MM, El-Sarnagawy GN, Nagy AA, Heshmat MM. Cardioprotective role of the coenzyme Q10 and coconut oil in acute aluminum phosphide poisoning: a randomized controlled clinical trial. Toxicol Res (Camb). 2023;12(3):507-19.
15. Karimani A, Mohammadpour AH, Zirak MR, Rezaee R, Megarbane B, Tsatsakis A, et al. Antidotes for aluminum phosphide poisoning: an update. Toxicol Rep. 2018;5:1053-9.
16. Moshiri M, Dorooshi G, Etemad L, Feizi A, Rahimi A, Gheshlaghi F, et al. Effect of extracorporeal membrane oxygenation on mortality rate of aluminum phosphate poisoning: a systematic review and meta-analysis. J Res Med Sci. 2024;29:62.
17. Mohan B, Gupta V, Ralhan S, Gupta D, Puri S, Mahajan R, et al. Impact of extra-corporeal membrane oxygenation on outcome of aluminium phosphide poisoning complicated with myocardial dysfunction. Clin Toxicol (Phila). 2019;57(11):1095-102.
18. Farrar RA, Justus BA, Masurkar VA, Garrett PM. Unexpected survival after deliberate phosphine gas poisoning: an Australian experience of extracorporeal membrane oxygenation rescue in this setting. Anaesth Intensive Care. 2022;50(3):250-4.
19. Shen Y, Jiang D, Wang T, Li M, Wang Y, Li J, et al. Blocking vicious cycle of cardiac dysfunction by external cardiopulmonary resuscitation is the key to rescue acute aluminium phosphide poisoning. Perfusion. 2023;38(1):214-9.
20. Dukhin O, Bala D, Felker E, Golovina P, Tretyakova M, Haes B, et al. Combination of veno-arterial extracorporeal membrane oxygenation and intra-aortic balloon pump in a young male patient with refractory cardiogenic shock due to aluminum phosphide poisoning. Front Cardiovasc Med. 2023;10:1226827.