Turkish Journal of Clinical Research

Turk J Clin Res. 2026;2(1):88-93
https://doi.org/10.63909/1453048

CASE REPORT

Assessment of the medial olivocochlear system in tympanic membrane perforation accompanied by hearing loss: A case report

İşitme kaybının eşlik ettiği kulak zarı perforasyonunda medial olivokoklear sistem değerlendirmesi: Bir olgu sunumu

Sule CEKIC[1], Pinar SAHIN[2]

[1]Ankara Yıldırım Beyazıt University, Faculty of Health Sciences, Department of Audiology, Ankara, Türkiye
[2]Ankara Yıldırım Beyazıt University, Institute of Health Sciences, Department of Audiology, Ankara, Türkiye

Abstract

The function of medial olivocochlear (MOC) system is commonly assessed with otoacoustic emissions (OAEs), which reflect outer hair cell activity. Integrity of the tympanic membrane (TM) is essential for reliable OAE responses. This case presents the hearing characteristics of a patient with chronic TM perforation and discusses MOC system function via OAE suppression. A 62-year-old female with a four-year history of unilateral chronic TM perforation and hearing loss in the right ear. Transient-evoked OAEs (TEOAEs) were recorded bilaterally. OAE suppression was assessed with contralateral narrowband noise. TEOAE amplitudes and suppression were analyzed. A suppression effect of 0.4 dB at 1 kHz was observed in the left ear, whereas no suppression was detected in the right ear. The findings indicate absent MOC suppression on the perforated side, suggesting that TM perforation in this case may reduce the effectiveness of the MOC efferent system in modulating cochlear amplification.

Keywords: Tympanic membrane, perforation, medial olivocochlear system.

Özet

Medial olivokoklear (MOC) efferent sistem değerlendirmeleri, dış tüylü hücrelerden elde edilen otoakustik emisyon (OAE) ölçümleri ile gerçekleştirilir. Kulak zarı bütünlüğünün OAE yanıtları elde edilebilmek için önemli olduğu bilinmektedir. Bu olgu sunumunda, kronik kulak zarı perforasyonu olan bir hastanın işitme özellikleri incelenmiş olup, OAE supresyonu yoluyla MOC sistem değerlendirmesi sunulmaktadır. Tek taraflı kronik kulak zarı perforasyonu olan 62 yaşında kadın hasta. Sağ kulakta 4 yıl önce oluşan kulak zarı perforasyonu ve işitme kaybı öyküsü var. Immitansmetrik ve odyometrik incelemeler yapıldı. Her iki kulak için TEOAE ölçümleri yapıldı. Kontralateral kulaktan 1 kHz'de NBN gönderilerek OAE supresyon ölçümleri yapıldı. TEAOE amplitüdleri değerlendirildi. Baskılanma miktarları sol kulakta 1 kHz'de 0,4 dB baskılanma, sağ kulakta 1 kHz'de baskılanma olmadığı elde edildi. Bu olguda hastanın zar perforasyonuna bağlı işitme özellikleri ve spesifik olarak MOC efferent sistem bulgusu sunuldu. TEOAE amplitüd değerinin supresyon etkisi ile değişmediği görüldü, perforasyon MOC sistemin etkinliğini azaltarak koklear amplifikasyonu yeterince modüle edilememesine yol açıyor olabilir.

Anahtar Kelimeler: Kulak zarı, perforasyon, medial olivokoklear sistem.

INTRODUCTION

The tympanic membrane (TM) is a semitransparent structure that separates the external ear from the middle ear. It converts acoustic energy into mechanical energy and transmits it to the ossicular chain in the middle ear. Tympanic membrane perforation refers to a rupture of this semitransparent structure and may occur as a result of infection, trauma, or sudden changes in pressure. While most perforations may heal spontaneously and close, some cases become chronic. Tympanic membrane perforation may lead to symptoms such as hearing loss, tinnitus, and vertigo (1). The location and size of the perforation influence the degree of hearing loss to

Corresponding Author: Sule CEKIC sulecekic@aybu.edu.tr
Cite as: Cekic S, Sahin P. Assessment of the medial olivocochlear system in tympanic membrane perforation: A case report. Turk J Clin Res. 2026;2(1):88-93

Content of this journal is licensed under a Creative Commons Attribution-NonCommercial-NonDerivatives 4.0 International License

Received: 1 January 2026 | **Accepted:** 29 April 2026 | **Published:** 31 May 2026

Turk J Clin Res. 2026;2(1):88-93
https://doi.org/10.63909/1453048

varying extents. As the size of the perforation increases, the vibrating area of the (TM) and the mobility of the stapes decrease, resulting in reduced acoustic energy transfer to the middle ear. Consequently, the degree of hearing loss increases (2).

Otoacoustic emissions (OAEs) are responses generated by the outer hair cells (OHCs) located in the cochlea and can be recorded via a sensitive microphone placed in the external auditory canal (3). In evoked OAE recordings, the stimulus must pass through the middle ear to reach the cochlea; therefore, any middle ear pathology may alter OAE responses (4). In cases of (TM) perforation, OAE responses are reduced or completely absent due to decreased acoustic energy transmission to the inner ear (5). Similarly, in age-related sensorineural hearing loss such as presbycusis, OAE responses are generally reduced or absent due to a decline in the number and function of outer hair cells (6).

The medial olivocochlear (MOC) system is a feedback mechanism that modulates the activity of outer hair cells in the cochlea via efferent fibers originating from the brainstem (7). Although there is no direct anatomical connection between the TM and the MOC system, the inhibitory effect of the MOC system on outer hair cells can be recorded in the external auditory canal. This inhibitory effect reduces cochlear amplification, thereby influencing the amplitude of backward-propagating OAEs, and these response variations are transmitted to the external ear through the middle ear and TM (7). Therefore, the TM functions as a passive transmission and measurement interface that reflects the effects of the MOC system.

Similar to middle ear muscle reflexes, the role of the MOC efferent system in the modulation of auditory signals indicates that the functional effects of both systems depend on middle ear transmission characteristics (8). In other words, changes in the transmission properties of the TM and middle ear affect middle ear muscle reflexes as well as OAE responses and the assessment of MOC efferent system function (8).

OAE suppression is a commonly used method for assessing the MOC efferent system. Activation of the MOC fibers by contralateral acoustic stimulation leads to suppression of outer hair cell electromotility, resulting in a reduction in OAE amplitudes (7,8). For suppression to be considered present, a minimum decrease of 0.5 dB SPL in OAE amplitude following contralateral noise stimulation is required (9).

In this case report, the pure tone audiometry and immittance test results, Transient Evoked OAE (TEOAE) measurements, and TEOAE suppression findings of an individual with unilateral chronic TM perforation are presented and discussed. Specifically, this case report aims to evaluate the effects of TM perforation on the MOC system using the TEOAE method.

CASE REPORT

A 62-year-old woman presented to a specialized hearing clinic with complaints of a sensation of water entering the right ear, mild hearing reduction, intermittent tinnitus, and increasing difficulty understanding speech in noisy environments. According to her medical history, these symptoms first appeared approximately five years earlier, and she had undergone an initial otologic evaluation at a tertiary care hospital four years prior to the present assessment. At that time, her primary complaints included a sensation of water entering the right ear, mild hearing reduction, and intermittent tinnitus. Over the subsequent years, her symptoms persisted and gradually worsened, with particular exacerbation of speech understanding difficulties in noisy listening conditions. The patient underwent tympanoplasty four years ago; however, postoperative follow-up revealed incomplete graft integration in the TM. At the time of the current evaluation, the patient did not state any history of head trauma, barotrauma, upper respiratory tract infections, or vertigo. No additional otologic or neurologic symptoms were reported.

At the time of the current evaluation; otoscopy, pure-tone audiometry, speech audiometry, immittance testing, TEOAE measurements, and TEOAE suppression tests were performed. Pure-tone audiometry was conducted using an Otometrics Madsen Astera2 audiometer, immittance measurements were obtained with an Otometrics Madsen Zodiac system, and TEOAE and TEOAE suppression measurements were carried out using an Otometrics Madsen Capella2 device. For suppression measurements, narrow-band noise (NBN) stimuli were delivered contralaterally via Otometrics insert earphones.

Turk J Clin Res. 2026;2(1):88-93
https://doi.org/10.63909/1453048

TEOAE responses were recorded from both the right and left ears using click stimuli presented at 60 dB SPL. The signal-to-noise ratio (SNR) criterion was set at 47 dB, and the number of sweeps was fixed at 512. Subsequently, a 1 kHz NBN stimulus at 60 dB SPL was presented to the contralateral ear via insert earphones, and the measurements were repeated. All measurements were performed in a sound-treated room. To ensure repeatability, each measurement was recorded twice, and data analysis was based on the average of the two recordings.

Otoscopy revealed a total perforation of the right TM, while the left TM appeared normal. Immittance testing demonstrated a Type B tympanogram in the right ear and a Type A tympanogram in the left ear (Figure 1). Ipsilateral acoustic reflexes were present in the left ear, whereas contralateral reflexes could not be elicited.

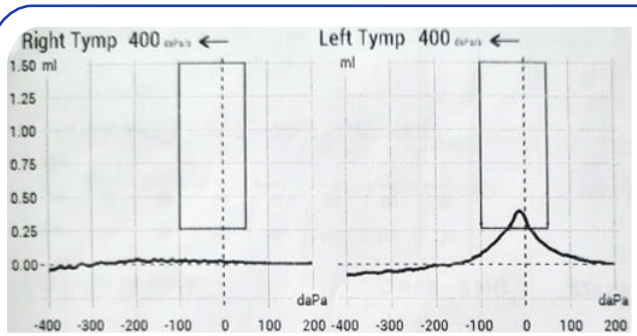

Figure 1. Tympanometry results

Pure-tone audiometry revealed mild sensorineural hearing loss in the left ear and severe mixed hearing loss in the right ear (Figure 2). Speech discrimination scores were 88% in the left ear and 60% in the right ear.

TEOAE measurements were performed in two modalities. Emissions were measured separately for each ear, and contralateral suppression was assessed using 1 kHz narrow-band noise (NBN) delivered to the opposite ear. All measurements were recorded twice, and TEOAE amplitudes were analyzed. The mean suppression values indicated 0.4 dB suppression at 1 kHz in the left ear, while no suppression was observed at 1 kHz in the right ear.

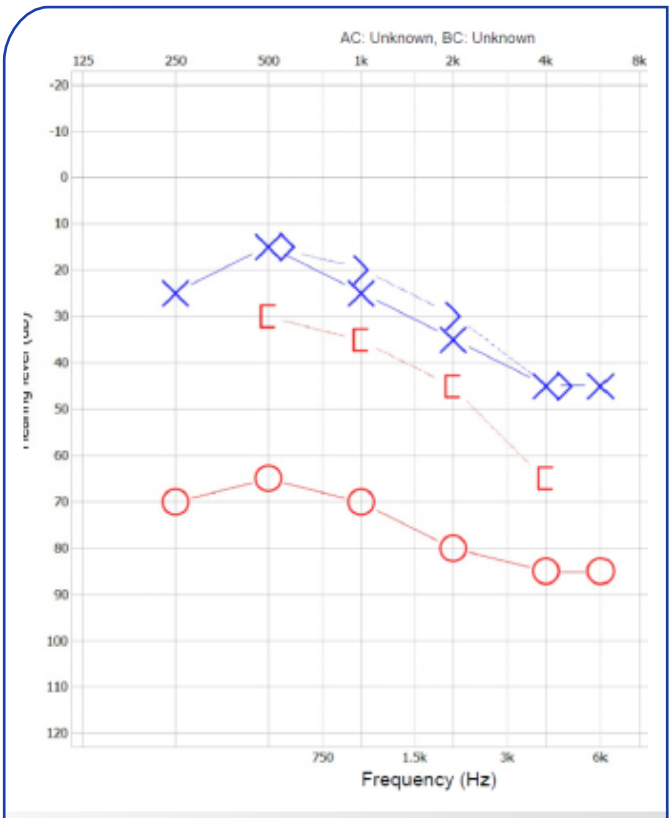

Figure 2. Pure-tone audiometry results

A representative visual of the measurements obtained during testing is presented as Figure 3.

Table 1. Right and left ear first and second TEOAE 1 kHz amplitude (dB) and SNR (dB) responses

	TEOAE Right Ear OAE 1 kHz Amplitude (dB)	TEOAE Right Ear OAE 1 kHz SNR (dB)	TEOAE Left Ear OAE 1 kHz Amplitude (dB)	TEOAE Left Ear OAE 1 kHz SNR (dB)
1st Measurement	0	1.2	-0.2	4
2st Measurement	0.9	2.1	0.8	3.7
Mean of 1st and 2nd Measurement	0.5	1.7	0.3	3.9

Abbreviations: *dB= decibel, NBN=Narrow-Band Noise, TEOAE=Transient Evoked Otoacoustic Emissions, SNR=signal-to-noise ratio*

Turk J Clin Res. 2026;2(1):88-93
https://doi.org/10.63909/1453048

Table 2. Right and left ear first and second TEOAE 1 kHz amplitude (dB) and SNR (dB) responses with suppression

	Suppression Test Right Ear OAE 1 kHz with cont. NBN Amplitude (dB)	Suppression Test Right Ear OAE 1 kHz with cont. NBN SNR (dB)	Suppression Test Left Ear OAE 1 kHz with cont. NBN Amplitude (dB)	Suppression Test Left Ear OAE 1 kHz with cont. NBN SNR (dB)
1st Measurement	1.5	4.8	0.4	5.1
2st Measurement	0.4	3.6	-0.6	7.4
Mean of 1st and 2nd Measurement	0.9	4.2	-0.1	6.2

Abbreviations: *dB= decibel, Cont.= Contralateral, NBN=Narrow-Band Noise, TEOAE=Transient Evoked Otoacoustic Emissions, SNR=signal-to-noise ratio*



Figure 2. Placement of insert earphone and emission probe

DISCUSSION

In this case report, the hearing characteristics of a patient with chronic TM perforation in the right ear, whose pure-tone audiometric thresholds were consistent with age-related expectations, were presented. The changes in TEOAE amplitude (dB) responses with contralateral acoustic stimulation were evaluated. Suppression of 0.4 dB at 1 kHz was observed in the left ear, while no suppression was detected at 1 kHz in the right ear. Previous studies emphasize that middle ear pathologies reduce the mobility of the TM and ossicular chain, thereby decreasing the acoustic energy transmitted to the inner ear (2). The acquisition of OAEs is closely related to middle ear mobility and outer hair cell integrity. Increases in hearing thresholds or pathological conditions that reduce middle ear mobility alter OAE amplitude responses, typically resulting in a decrease (10). This case report is of importance as it demonstrates that TEOAE amplitudes and suppression responses may reflect not only the activity of the MOC efferent system but also middle ear transmission characteristics.

Tympanic membrane perforations may heal spontaneously in some patients, whereas others require surgical intervention (11). In certain cases, the underlying reparative mechanisms fail, resulting in chronic perforation. In this patient, although tympanoplasty was performed at initial diagnosis, postoperative follow-up showed incomplete graft integration. Given the patient's age, a second tympanoplasty would have a reported success rate of approximately 20%, and therefore the patient did not undergo repeat surgery. This condition contributes to conductive hearing loss (12). Accordingly, this patient exhibited mixed-type hearing loss in the right ear with TM perforation. Age-related presbycusis also coexisted, contributing to sensorineural hearing loss in the left ear and supporting the observed mixed-type hearing loss in the right ear.

The current literature on OAE suppression assessment in TM perforation is limited. Middle ear pathologies alter OAE responses, and OAE amplitudes are associated with hearing thresholds and middle ear dynamics. While OAE responses can be obtained in hearing losses up to 40

Turk J Clin Res. 2026;2(1):88-93
https://doi.org/10.63909/1453048

dB, responses are generally not expected beyond this threshold (10). In this patient, the right ear's hearing loss exceeding 40 dB likely contributed to the low amplitude and limited reliability of TEOAE responses. The absence of suppression in the right ear suggests that the suppression response may have been attenuated due to impaired middle ear transmission.This case highlights that in hearing losses accompanied by a conductive component, such as tympanic membrane perforation, MOC reflex assessment should not only be interpreted using standard approaches but also evaluated within the broader clinical context.

Changes in OAE suppression are dependent on MOC efferent system activity. A recent systematic review (2025) highlighted the importance of middle ear muscle activation responses in MOC assessment (9). In line with this, ipsilateral acoustic reflexes were observed in the left ear, but contralateral reflexes were absent. In the perforated right ear, no reflexes could be recorded. Similarly, TEOAE suppression evaluation revealed amplitude changes in the left ear but no changes in the right ear, supporting current literature findings.

No studies have directly evaluated MOC efferent system function in patients with TM perforation. However, several studies have investigated the effects of TM perforation on OAE responses (13). Research on DPOAE responses indicates that small perforations allow measurable OAE responses, whereas larger perforations reduce responses, particularly at higher frequencies, corroborating the findings observed in our case.

Leslie et al. investigated whether lifelong reduction of acoustic exposure protects the cochlea in age-related hearing loss. In adult mice, one group underwent complete TM removal, while another group had the olivocochlear system removed. Chronic conductive hearing loss increased cochlear afferent synaptopathy and significantly reduced olivocochlear efferent innervation. While TM perforation primarily affects the lateral olivocochlear system, it also weakens the MOC efferent system (14). This effect leads to reduced or absent OAE suppression, consistent with the results observed in our patient.

Studies in normal-hearing individuals with intact TM have shown that contralateral noise-induced reductions in OAE amplitude reflect the inhibitory effect of the MOC system on outer hair cells and functional activation of the efferent feedback mechanism (15). The absence of OAE suppression in the ear with TM perforation in this case aligns with these findings.

Although the primary aim of this case report was not to present the optimal hearing rehabilitation strategy for the patient, we would like to note that the patient was counseled regarding appropriate hearing aid use and provided with detailed information. It's known that due to age-related hearing loss, if no intervention is implemented, the negative consequences of hearing loss may progress over time. Speech discrimination scores may decline, further impairing the ability to understand speech in noisy environments.

This case contributes to the existing literature by highlighting the specific challenges in interpreting MOC efferent system assessments in hearing losses involving both conductive and sensorineural components. The MOC reflex has predominantly been investigated in normal-hearing individuals or in cases with isolated sensorineural hearing loss, and data regarding the influence of a conductive component on efferent system measurements remain limited. The present case underscores the factors affecting MOC suppression responses in a clinical condition where tympanic membrane perforation coexists with age-related sensorineural hearing loss.

The primary limitation of this case report is that the hearing loss in the ear with tympanic membrane perforation was of mixed type. The presence of a conductive component may reduce OAE amplitudes and the associated SNR, thereby limiting the measurability of MOC system suppression. Consequently, the absence of observable TEOAE suppression in the perforated ear may be due not only to reduced MOC efferent system activity but also to low baseline emission responses. In addition, in this case report, the presence of age-related sensorineural hearing loss (presbycusis) may pose a challenge in the evaluation process. Although presbycusis predominantly affects higher frequencies and the assessments were conducted at 1 kHz, its contribution to the findings is considered limited.

Turk J Clin Res. 2026;2(1):88-93
https://doi.org/10.63909/1453048

CONCLUSION

In conclusion, chronic TM perforation, a pathological condition causing conductive hearing loss, together with age-related hearing loss, reduced the effectiveness of the MOC efferent system. This suggests that the MOC efferent system cannot adequately modulate cochlear amplification, which may contribute to difficulties in understanding speech in noisy environments. This case draws attention to the methodological challenges encountered in interpreting MOC system measurements in the presence of a conductive component and underscores the need for further studies involving cases with isolated conductive hearing loss.

Acknowledgement: The authors would like to express their sincere gratitude to Audiology Specialist Sami AKTAŞ for his continuous technical support and valuable contributions.

Ethical Approval: As this is a case report, ethical approval was not required for this report. Written informed consent was obtained from the patient prior to participation.

Author Contributions: Idea/Concept: S.C., P.S.; Design: S.C., P.S.; Supervision: S.C.; Resources: S.C., P.S.; Materials: S.C., P.S.; Data Collection and/or Processing: P.S.; Analysis and/or Interpretation: S.C., P.S.; Literature Review: S.C., P.S.; Written by: S.C., P.S.; Critical Review: S.C., P.S.

Conflict of Interest: The authors declared no conflict of interest related to this study.

Financial Disclosure: The authors declared that this study has received no financial support.

REFERENCES

1. Sinkkonen ST, Jero J, Aarnisalo AA. Tympanic membrane perforation. Duodecim. 2014;130(8):810-8.
2. Aslıer M, Özay H, Gürkan S, Kırkım G, Güneri EA. The effect of tympanic membrane perforation site, size and middle ear volume on hearing loss. Turk Arch Otorhinolaryngol. 2019;57(2):86-90.
3. Kemp DT. Stimulated acoustic emissions from within the human auditory system. J Acoust Soc Am. 1978;64(5):1386-91.
4. Koike KJ, Wetmore SJ. Interactive effects of the middle ear pathology and the associated hearing loss on transient-evoked otoacoustic emission measures. Otolaryngol Head Neck Surg. 1999;121(3):238-44.
5. Ueda H, Nakata S, Hoshino M. Effects of effusion in the middle ear and perforation of the tympanic membrane on otoacoustic emissions in guinea pigs. Hear Res. 1998;122(1-2):41-6.
6. Oeken J, Lenk A, Bootz F. Influence of age and presbyacusis on DPOAE. Acta Otolaryngol. 2000;120(3):396-403.
7. Guinan JJ Jr. Olivocochlear efferents: anatomy, physiology, function, and the measurement of efferent effects in humans. Ear Hear. 2006;27(6):589-607.
8. Marks KL, Siegel JH. Differentiating middle ear and medial olivocochlear effects on transient-evoked otoacoustic emissions. J Assoc Res Otolaryngol. 2017;18(4):529-42.
9. Silva JDD, Leal Gouveia MC, Hora LCDD, Venancio LGÂ, Muniz LF. Effect of suppression of otoacoustic emissions in individuals with and without central auditory processing disorder: a systematic review. Braz J Otorhinolaryngol. 2025;91(1):101485.
10. Zhao F, Wada H, Koike T, Ohyama K, Kawase T, Stephens D. Transient evoked otoacoustic emissions in patients with middle ear disorders. Int J Audiol. 2003;42(3):117-31.
11. Govaerts PJ, Jacob WA, Marquet J. Histological study of the thin replacement membrane of human tympanic membrane perforations. Acta Otolaryngol. 1988;105(3-4):297-02.
12. Röösli C, von Büren T, Gassmann NB, Huber AM. The impact of platelet-derived growth factor on closure of chronic tympanic membrane perforations: a randomized, double-blind, placebo-controlled study. Otol Neurotol. 2011;32(8):1224-9.
13. Dong W, Stomackin G, Lin X, Martin GK, Jung TT. Distortion product otoacoustic emissions: sensitive measures of tympanic-membrane perforation and healing processes in a gerbil model. Hear Res. 2019;378:3-12.
14. Liberman MC, Liberman LD, Maison SF. Chronic conductive hearing loss leads to cochlear degeneration. PLoS One. 2015;10(11):e0142341.
15. Jedrzejczak WW, Milner R, Ganc M, Pilka E, Skarzynski H. No change in medial olivocochlear efferent activity during an auditory or visual task: dual evidence from otoacoustic emissions and event-related potentials. Brain Sci. 2020;10(11):894.