Turkish Journal of Clinical Research

Turk J Clin Res. 2026;2(2):202-206
https://doi.org/10.63909/1453060

CASE REPORT

Basilar fusiform aneurysm with occluded flow diverter stent: What can we do?

Oklüde akım yönlendirici stentli baziler fuziform anevrizma: Ne yapabiliriz?

Ridvan ACIKALIN[1], Mahmut FERAT[2]

[1]İstinye University, Department of Neurosurgery, İstanbul, Türkiye
[2]Ministry of Health Adana City Training and Research Hospital, Department of Neurosurgery, Adana, Türkiye

Abstract

Occlusion of a flow diverter construct can complicate the management of vertebrobasilar fusiform aneurysms. A 56-year-old man with nausea, vomiting, headache, dysmetria, and dysdiadochokinesia underwent placement of two flow diverter stents for a fusiform aneurysm extending from the left vertebral artery to the basilar artery. Nine months later, worsening symptoms prompted angiography, which demonstrated left vertebral artery occlusion, narrowing of the proximal stent, aneurysm enlargement, and new thrombus formation. Recanalization was abandoned because of the thrombus burden. A third flow diverter was deployed from the right vertebral artery into the basilar artery through the existing stent struts after sequential balloon dilation, creating a reverse Y configuration. Computed tomography angiography at one month showed satisfactory expansion at the crossing site. Two-month angiography showed decreased aneurysm size, with partial symptom improvement. This case illustrates a technically feasible rescue approach with short-term follow-up.

Keywords: Basilar artery, fusiform aneurysm, intracranial aneurysm, stents, endovascular procedures.

Özet

Akım yönlendirici stent sisteminin oklüzyonu, vertebrobaziler fuziform anevrizmaların tedavisini güçleştirebilir. Bulantı, kusma, baş ağrısı, dismetri ve disdiadokokinezi ile başvuran 56 yaşındaki erkek hastada, sol vertebral arterden baziler artere uzanan fuziform anevrizma iki akım yönlendirici stent ile tedavi edildi. Dokuz ay sonra yakınmaların kötüleşmesi üzerine yapılan anjiyografide sol vertebral arter oklüzyonu, proksimal stentte daralma, anevrizmada genişleme ve yeni trombüs oluşumu görüldü. Trombüs yükü nedeniyle rekanalizasyon girişimi sonlandırıldı. Mevcut stentin hücreleri içinden geçilerek ardışık balon dilatasyonu uygulandı ve sağ vertebral arterden baziler artere üçüncü bir akım yönlendirici stent ters Y konfigürasyonunda yerleştirildi. Birinci ay bilgisayarlı tomografi anjiyografisinde geçiş bölgesinde yeterli stent açıklığı izlendi. İkinci ay anjiyografisinde anevrizma boyutunda küçülme saptandı ve hastanın yakınmaları kısmen geriledi. Bu olgu, kısa süreli takipte teknik olarak uygulanabilen bir kurtarma yaklaşımını göstermektedir.

Anahtar Kelimeler: Baziler arter, fusifom anevrizma, intrakraniyal anevrizma, stentler, endovasküler işlemler.

INTRODUCTION

Intracranial aneurysms can be classified by pathogenesis, morphology, or etiology. Morphologically, they are divided into saccular and nonsaccular aneurysms. Fusiform aneurysms are nonsaccular dilatations involving a variable length of the vessel wall. They account for approximately 3–13% of intracranial aneurysms and frequently involve the vertebrobasilar circulation (1). Their clinical presentation and endovascular management are heterogeneous (2,3,4).

Disruption of the internal elastic lamina may create communication between the true lumen and a false lumen. Progression toward the adventitia may result in rupture and subarachnoid hemorrhage, whereas expansion within the arterial wall may cause luminal narrowing and ischemia (5). The natural history of vertebrobasilar fusiform aneurysms can be unfavorable (6). A prospective study reported an annual rupture rate of 2.3% for fusiform vertebrobasilar aneurysms (7). An initial diameter greater than 10 mm has been associated with enlargement and subsequent rupture, and aneurysm growth has been associated with increased mortality (7,8).

Corresponding Author: Mahmut FERAT mahmutferatmd@gmail.com
Cite as: Acikalin R, Ferat M. Basilar fusiform aneurysm with occluded flow diverter stent: what can we do? Turk J Clin Res. 2026;2(2):202-206

Content of this journal is licensed under a Creative Commons Attribution-NonCommercial-NonDerivatives 4.0 International License

Received: 17 January 2026 | **Accepted:** 28 September 2026 | **Published:** 30 September 2026

Turk J Clin Res. 2026;2(2):202-206
https://doi.org/10.63909/1453060

The heterogeneous pathology and clinical course of fusiform aneurysms complicate treatment selection (9,10). Aneurysm size, symptoms, and posterior circulation location are relevant to the assessment of rupture risk and outcome (11,12,13). We describe a rescue procedure for a symptomatic vertebrobasilar fusiform aneurysm after occlusion of the vertebral component of a previously implanted flow diverter construct.

CASE PRESENTATION

A 56-year-old man presented to the emergency department with nausea, vomiting, and headache. Physical examination revealed dysmetria and dysdiadochokinesia. Cerebral computed tomography angiography (CTA) demonstrated a proximal basilar fusiform aneurysm with mural thrombus and compression of the anterior aspect of the brainstem. The left vertebral artery was dominant. The aneurysm extended from the distal left V4 segment to the mid-basilar artery. Diagnostic angiography confirmed involvement of the distal left vertebral artery and basilar artery (Figure 1).



Figure 1. Baseline angiography demonstrating a fusiform aneurysm involving the distal left vertebral artery and basilar artery

Two flow diverter stents were placed from the left vertebral artery V4 segment to the distal basilar artery by another department at the same hospital. The proximal portion of the second, longer stent was incompletely expanded. Balloon dilation improved its diameter, although wall apposition of both stents remained suboptimal.

Nine months later, the patient presented to our angiography unit with worsening symptoms. Digital subtraction angiography (DSA) demonstrated occlusion of the left vertebral artery and narrowing of the proximal stent at the proximal basilar artery. Basilar artery flow was supplied solely by the right vertebral artery. The aneurysm had enlarged at the vertebrobasilar junction, with filling defects attributed to new thrombus formation (Figure 2). We suspected that the existing stent struts restricted inflow from the right vertebral artery, contributing to flow stagnation and increased local pressure. This hemodynamic interpretation remains inferential.

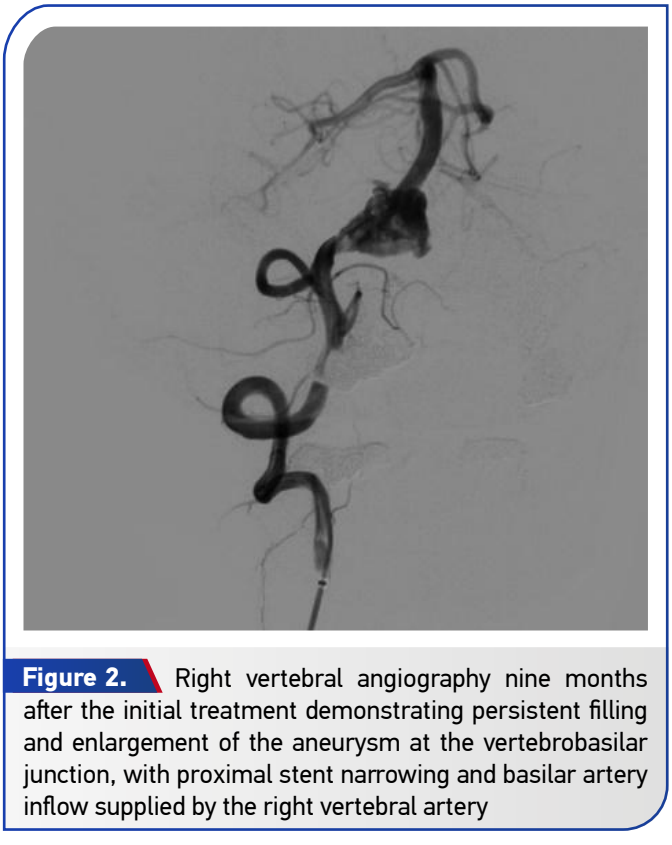

Figure 2. Right vertebral angiography nine months after the initial treatment demonstrating persistent filling and enlargement of the aneurysm at the vertebrobasilar junction, with proximal stent narrowing and basilar artery inflow supplied by the right vertebral artery

An initial attempt to recanalize the occluded left vertebral artery was abandoned because of the substantial thrombus burden. We therefore planned to deploy an additional flow diverter from the right vertebral artery into the basilar artery through the struts of the existing stent.

Turk J Clin Res. 2026;2(2):202-206
https://doi.org/10.63909/1453060

Because the right vertebral artery had become the sole source of basilar artery inflow, we favored a reconstructive strategy that preserved this patent vertebrobasilar pathway. After recanalization of the occluded left vertebral artery was considered unsafe because of the thrombus burden, passage through the existing stent struts from the right vertebral artery offered a feasible route for additional flow diversion while maintaining basilar artery perfusion.

Under general anesthesia, a 6-French long sheath and a 5-French guiding catheter were advanced coaxially to the right vertebral artery V4 segment. We initially attempted to cross the struts at the narrowed proximal segment of the longer stent, where we considered the cells to be more accessible. A Headway Duo microcatheter with a 0.010-inch microwire could not cross the stent wall. An SL-10 microcatheter and a 0.014-inch Synchro microwire were subsequently advanced through the struts into the basilar artery lumen. The microwire was exchanged for a 300-cm Synchro 2 Support exchange guidewire.

A 1.5 × 20-mm monorail coronary balloon catheter could not cross the stent wall. A 3 × 8-mm Neurospeed percutaneous transluminal angioplasty balloon catheter was then advanced through the struts and used for dilation. Further dilation was performed with a 4 × 100-mm Coyote peripheral monorail balloon catheter. The balloon catheter was exchanged for a Headway 27 microcatheter, and a 5.5 × 26-mm FRED X flow diverter was deployed from the right V4 segment to the mid-basilar artery in a reverse Y configuration (Figure 3).

Periprocedural antiplatelet therapy consisted of prasugrel (Effient): five 10-mg tablets (total dose, 50 mg) were administered perioperatively, followed by 10 mg once daily during follow-up. No procedure-related neurological, thromboembolic, hemorrhagic, vascular or systemic complications were observed, and no new postoperative neurological deficit occurred.

Cone-beam computed tomography was unavailable on the angiography system. Cranial CTA performed one month after retreatment demonstrated satisfactory stent expansion at the point of passage through the existing stent wall (Figure 4). Follow-up DSA at two months showed decreased aneurysm size, and the patient's symptoms had partially improved (Figure 5).

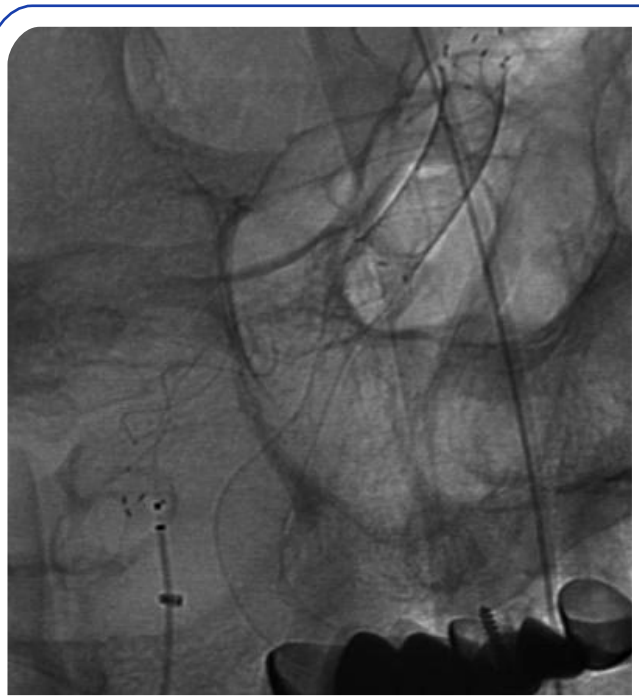

Figure 3. Fluoroscopic image during deployment of the additional flow diverter from the right vertebral artery into the basilar artery after crossing and sequential dilation of the existing stent struts, creating a reverse Y configuration

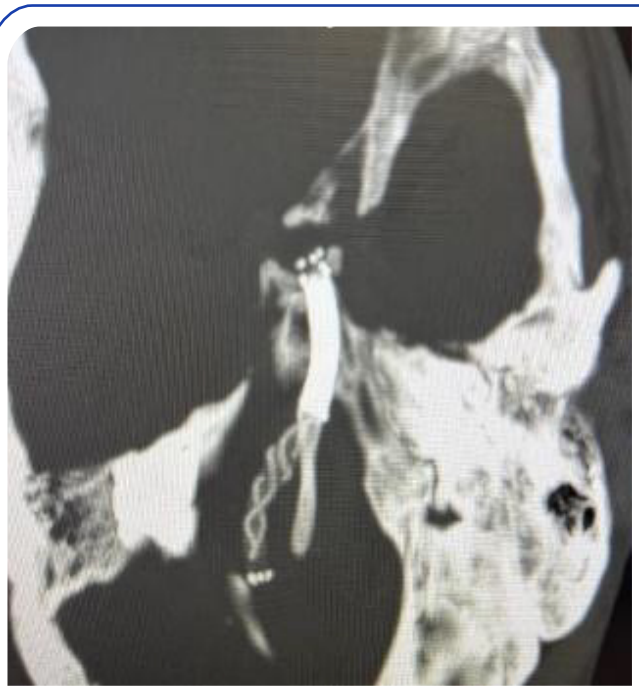

Figure 4. Computed tomography angiography one month after retreatment demonstrating satisfactory expansion of the new flow diverter at the crossing point through the wall of the previously implanted stent

Turk J Clin Res. 2026;2(2):202-206
https://doi.org/10.63909/1453060

Clinical follow-up at 3 and 6 months showed no new neurological deficit. A follow-up digital subtraction angiography is planned at 12 months to assess the durability of the reconstruction and aneurysm evolution.

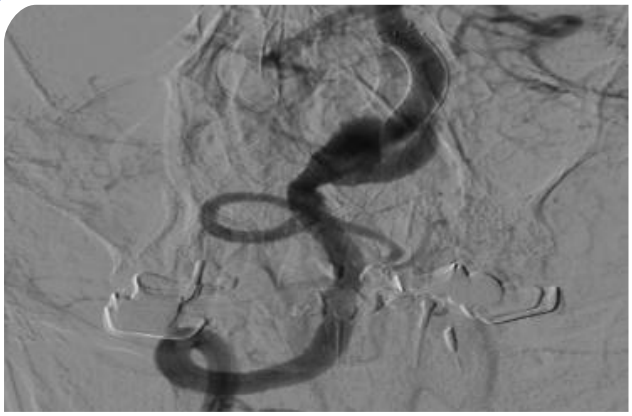

Figure 5. Follow-up digital subtraction angiography two months after retreatment demonstrating reduced aneurysm size with preserved vertebrobasilar flow through the reconstructed segment

DISCUSSION

Fusiform aneurysms differ from saccular aneurysms in their underlying pathology, hemodynamics, anatomical distribution, natural history, and treatment. Dissection and atherosclerosis are major causes; collagen and elastin disorders, infection, neoplastic invasion, and iatrogenic injury are other possible etiologies. Symptomatic patients, particularly those with brainstem ischemia or compression, may have an unfavorable natural history (1).

Reconstructive endovascular treatment with stents and flow diverters offers an alternative to deconstructive approaches, but changes in aneurysm hemodynamics and perforator-related complications remain concerns (14,15). Questions regarding adjunctive coiling, unilateral vertebral artery occlusion, and staged treatment require individualized consideration.

In the present case, alternative strategies were limited by the occluded left vertebral artery, the substantial thrombus burden, and dependence of the basilar circulation on the right vertebral artery. For these reasons, a contralateral reconstructive approach was selected rather than further manipulation of the thrombosed left-sided construct or a deconstructive strategy that could jeopardize the remaining basilar inflow.

In our department, the initial approach is generally to place a single long flow diverter and assess the response, with additional telescoping devices if necessary. In the present case, two previously implanted stents had suboptimal wall apposition, and the vertebral component subsequently occluded. The remaining vertebral artery became the sole source of basilar artery inflow. We interpreted the angiographic enlargement and new thrombus formation as possible consequences of restricted flow through the existing stent struts. This proposed mechanism remains inferential.

Deployment of a third flow diverter from the contralateral vertebral artery required crossing and sequentially dilating the existing stent struts. This established a reverse Y configuration and was followed by satisfactory expansion on one-month CTA, reduced aneurysm size on two-month DSA, and partial clinical improvement. These observations describe technical feasibility in one patient. The short follow-up and lack of reported quantitative aneurysm measurements or standardized neurological outcome scores limit conclusions about durability and clinical effectiveness.

Crossing and balloon dilation of a previously implanted flow-diverter construct may carry specific technical risks. These include deformation or disruption of the pre-existing stent, vessel injury during strut crossing or angioplasty, thromboembolic events, incomplete expansion or malapposition of the newly implanted device, and potential compromise of perforating branches. In this setting, gradual sequential dilation and careful angiographic assessment are important to minimize mechanical injury and to confirm adequate expansion of the crossing construct.

CONCLUSION

In this case, crossing and dilating the struts of an existing flow diverter enabled contralateral vertebrobasilar reconstruction in a reverse Y configuration after occlusion of the original vertebral inflow. Short-term imaging showed decreased aneurysm size, accompanied by partial symptom improvement. Longer follow-up is needed to assess the durability of this rescue approach.

Turk J Clin Res. 2026;2(2):202-206
https://doi.org/10.63909/1453060

Acknowledgement: None.

Ethical Approval: Ethical committee approval was not required for this single-patient case report in accordance with institutional policy.

Informed Consent: Written informed consent was obtained from the patient using a standard consent form that included authorization for the use of clinical information in scientific publications.

Author Contributions: Idea/Concept: M.F.; Design: M.F.; Supervision: M.F., R.A.; Resources: M.F., R.A.; Materials: M.F., R.A.; Data Collection and/or Processing: M.F., R.A.; Analysis and/or Interpretation: M.F., R.A.; Literature Review: M.F., R.A.; Written by: M.F., R.A.; Critical Review: M.F.

Conflict of Interest: The authors declare that there is no conflict of interest.

Financial Disclosure: The authors declare that they received no financial support for this study.

REFERENCES

1. Park SH, Yim MB, Lee CY, Kim E, Son EI. Intracranial fusiform aneurysms: its pathogenesis, clinical characteristics and managements. J Korean Neurosurg Soc. 2008;44:116-23.
2. Kim BM, Shin YS, Kim SH, Suh SH, Ihn YK, Kim DI, et al. Incidence and risk factors of recurrence after endovascular treatment of intracranial vertebrobasilar dissecting aneurysms. Stroke. 2011;42:2425-30.
3. Kan P, Mokin M, Puri AS, Wakhloo AK. Successful treatment of a giant pediatric fusiform basilar trunk aneurysm with surpass flow diverter. J Neurointerv Surg. 2016;8(6):e23.
4. Onofrj V, Cortes M, Tampieri D. The insidious appearance of the dissecting aneurysm: imaging findings and related pathophysiology. A report of two cases. Interv Neuroradiol. 2016;22:638-42.
5. Ota N, Tanikawa R, Kamiyama H, Miyazaki T, Noda K, Katsuno M, et al. Discrepancy between preoperative imaging and postoperative pathological finding of ruptured intracranial dissecting aneurysm, and its surgical treatment: case report. Neurol Med Chir (Tokyo). 2014;54:219-26.
6. Echiverri HC, Rubino FA, Gupta SR, Gujrati M. Fusiform aneurysm of the vertebrobasilar arterial system. Stroke. 1989;20:1741-7.
7. Flemming KD, Wiebers DO, Brown RD Jr, Link MJ, Nakatomi H, Huston J 3rd, et al. Prospective risk of hemorrhage in patients with vertebrobasilar nonsaccular intracranial aneurysm. J Neurosurg. 2004;101:82-7.
8. Mangrum WI, Huston J 3rd, Link MJ, Wiebers DO, McClelland RL, Christianson TJ, et al. Enlarging vertebrobasilar nonsaccular intracranial aneurysms: frequency, predictors, and clinical outcome of growth. J Neurosurg. 2005;102:72-9.
9. Mizutani T, Miki Y, Kojima H, Suzuki H. Proposed classification of nonatherosclerotic cerebral fusiform and dissecting aneurysms. Neurosurgery. 1999;45(2):253-9.
10. Drake CG, Peerless SJ. Giant fusiform intracranial aneurysms: review of 120 patients treated surgically from 1965-1992. J Neurosurg. 1997;87:141-62.
11. Rinkel GJ, Djibuti M, Algra A, van Gijn J. Prevalence and risk of rupture of intracranial aneurysms: a systematic review. Stroke. 1998;29(1):251-6.
12. Schievink WI, Wijdicks EF, Piepgras DG, Chu CP, O'Fallon WM, Whisnant JP. The poor prognosis of ruptured intracranial aneurysms of the posterior circulation. J Neurosurg. 1995;82(5):791-5.
13. International Study of Unruptured Intracranial Aneurysms Investigators. Unruptured intracranial aneurysms-risk of rupture and risks of surgical intervention. N Engl J Med. 1998;339:1725-33.
14. Cebral JR, Mut F, Raschi M, Scrivano E, Ceratto R, Lylyk P, et al. Aneurysm rupture following treatment with flow-diverting stents: computational hemodynamics analysis of treatment. AJNR Am J Neuroradiol. 2011;32(1):27-33.
15. van Rooij WJ, Sluzewski M. Perforator infarction after placement of a pipeline flow-diverting stent for an unruptured A1 aneurysm. AJNR Am J Neuroradiol. 2010;31(4):43-4.