Turkish Journal of Clinical Research

Turk J Clin Res. 2025;1(3):164-170
https://doi.org/10.63909/1453027

RESEARCH ARTICLE

Relationship of foramen magnum morphology with gender and age

Foramen magnum morfolojisinin cinsiyet ve yaş ile ilişkisi

Hatice YENIGUL[1], Serdar COLAKOGLU[2], Yusuf SECGIN[3], Omer ONBAS[4]

[1]Arel University, Faculty of Medicine, Department of Anatomy, İstanbul, Türkiye
[2]Düzce University, Faculty of Medicine, Department of Anatomy, Düzce, Türkiye
[3]Karabük University, Faculty of Medicine, Department of Anatomy, Karabük, Türkiye
[4]Düzce University, Faculty of Medicine, Department of Radiodiagnostics, Düzce, Türkiye

Abstract

Aim: The determination of the morphological characteristics of the foramen magnum (FM) specific to gender, age and the individual plays an important role in the identification processes in the fields of forensic medicine and anthropology. It also holds an important place in the planning of various surgical approaches, particularly neurosurgery. Therefore, detailed analysis of the anatomical variations of the FM contributes significantly to both anthropology and clinical practice. The aim of our study is to evaluate the shape of the FM according to age and gender using three-dimensional (3D) images of the skull.

Methods: In our study, the CT data of the skull from 250 men and 250 women aged 20-69 were orthogonally aligned in the horizontal, sagittal and coronal planes using the 3D MPR (Multiplanar Reformat) tool. 3D skull images were obtained from the CT slices. The individuals in our study were divided into five different age groups: 20-29, 30-39, 40-49, 50-59 and 60-69 with 100 individuals (50 men, 50 women) in each age group. The morphological classification of the FM was analyzed according to gender and age using the Pearson Chi-Square test.

Results: FM was found to have eight different morphological variations: Hexagonal, round, octagonal, egg-shaped, oval, pentagonal, tetragonal and irregular. No statistically significant difference in shape was found between males and females of FM ($p>0.05$). However, the morphological analysis of FM according to age groups revealed a statistically significant difference ($p<0.05$).

Conclusion: The study found that FM has eight different morphological structures and that this variation shows age-related changes. However, no gender-specific changes were identified. We believe that this result will contribute to the identification studies of clinicians performing surgical procedures in this region and to the science of forensic medicine and anthropology.

Keywords: Foramen magnum, morphology, age, gender.

Özet

Amaç: Foramen magnum'un (FM) cinsiyete, yaşa ve bireye özgü olarak morfolojik özelliklerin belirlenmesi; adli tıp ve antropoloji alanlarında kimlik tespiti süreçlerinde önemli rol alır. Ayrıca nöroşirürji başta olmak üzere çeşitli cerrahi yaklaşımların planlanmasında önemli bir yere sahiptir. Bu nedenle, FM'un anatomik varyasyonlarının detaylı biçimde analiz edilmesi, hem antropoloji hem de klinik uygulama alanlarında önemli katkılar sunmaktadır. Çalışmamızdaki amacımız, cranium'a ait üç boyutlu (3B) görüntüler üzerinden FM'un şekilsel olarak yaşa ve cinsiyete göre değerlendirilmesidir.

Yöntemler: Çalışmamızda 20-69 yaş aralığındaki 250 erkek, 250 kadın bireyin cranium'un Bilgisayarlı Tomografi (BT) verileri üzerinden 3D MPR (Multiplanar Reformat) aracı kullanılarak horizontal, sagittal ve koronal düzlemlerde ortogonal hale getirildi. BT kesitleri üzerinden 3B cranium görüntüleri elde edildi. Çalışmamızdaki bireyler 20-29, 30-39, 40-49, 50-59 ve 60-69 olmak üzere beş farklı yaş grubuna ayrılarak her yaş grubunda 100 (50 erkek, 50 kadın) birey belirlendi. FM'un şekilsel olarak sınıflandırılması cinsiyete ve yaşa göre analizi Pearson Ki-Kare testi ile değerlendirildi.

Bulgular: FM altıgen, yuvarlak, sekizgen, yumurta, oval, beşgen, dörtgen ve düzensiz olmak üzere sekiz farklı morfolojik farklılığa sahip olduğu belirlendi. FM'un şekilsel olarak cinsiyete göre istatistiksel olarak anlamlı bir fark olmadığı tespit edildi ($p>0,05$). Yaş gruplarına göre FM'un şekilsel olarak analiz sonucunda ise istatistiksel olarak anlamlı bir fark olduğu belirlendi ($p<0,05$).

Sonuç: Çalışma sonucunda FM'un sekiz farklı morfolojik yapıya sahip olduğu ve bu farklılığın yaşa bağlı değişiklik gösterdiği tespit edildi. Ancak cinsiyete özgü herhangi bir değişiklik olmadığı belirlendi. Bu elde edilen sonucun bu bölgede cerrahi girişim yapan klinisyenlere, adli tıp ve antropoloji bilimine kimlik tespiti çalışmalarında katkı sağlayacağı kanaatindeyiz.

Anahtar Kelimeler: Foramen magnum, morfoloji, yaş, cinsiyet.

INTRODUCTION

The foramen magnum (FM) is located in the posterior cranial fossa at the posterior inferior part of the skull. This anatomical structure, situated between the lateral part (two) the basilar part and the squama of the occipital bone, forms the connection point between the cerebrum and the spinal cord. In addition to the spinal cord, the anterior spinal artery, posterior spinal artery, vertebral arteries, tectorial membrane and spinal part

Corresponding Author: Hatice YENIGUL haticeyenigul@arel.edu.tr
Cite as: Yenigul H, Colakoglu S, Secgin Y, Onbas O. Effect of vitamin D replacement in patients with heart failure on six minute walking test and echocardiographic parameters. Turk J Clin Res. 2025;1(3):164-170

Content of this journal is licensed under a Creative Commons Attribution-NonCommercial-NonDerivatives 4.0 International License

Received: 30 October 2025 | **Accepted:** 30 November 2025 | **Published:** 31 December 2025

Turk J Clin Res. 2025;1(3):164-170
https://doi.org/10.63909/1453027

of the accessory nerve pass through this structure (1–3). The first region to mature in the skull is the base of the skull. The development of the base of the skull influences the shape of the skull and neurocranium. The sagittal length of the FM can reach adult size by age 5. However, its transverse length continues to grow until age 10. The shape of the FM can change until the age range of 5-10 years. The shape of the FM also varies during this age period depending on environmental factors (such as sleeping position and cranial fixation). It is particularly affected by sleep position and the effects of gravity during infancy. If the skull is bound in an anterior-posterior direction, the base of the skull widens, while if it is bound circumferentially, the FM may tend to elongate in the sagittal direction. In this context the shape of the FM can be influenced by external factors applied during infancy (4,5).

FM is an important anatomical structure that varies morphologically between individuals and possesses unique structural characteristics. These variations are shaped by various biological markers such as gender, age, ethnicity and genetic factors (1,6). Although anatomy books generally describe it as having an oval shape, various studies have indicated that the FM can be observed in different morphological forms such as round, egg-shaped, pentagonal and hexagonal (6,8,9). This diversity demonstrates that the FM possesses a unique anatomy that can take different forms in each individual. Morphological variations are not merely limited to differences in shape; they can also affect the functions of vital structures passing through the FM (spinal cord, anterior spinal artery etc.) and can be directly decisive in the planning process of surgical approaches to this region. Therefore, determining the morphological characteristics of the FM is of great importance in terms of neurosurgery and craniocervical surgical practices, as well as in making predictions about the biological origins of the individual (1,8). Additionally, findings in the literature indicate that the FM shape may vary according to gender and age (10,11).

Among imaging technologies, Computed Tomography (CT) is widely used in forensic anthropology, particularly in identification studies. CT enables the virtual reconstruction of highly fragmented or burned human skeletal remains, making it a reliable method for gender estimation studies (12). Three-dimensional (3D) models derived from CT images enable the comprehensive evaluation of anatomical structures. In this context, measurements can be both visualized and analyzed more accurately and in greater detail (13).

The shape of the FM has been examined across various population samples of different age groups and genders. This shape-based classification has varied from study to study and the incidence of the results obtained differs (11,14). The shape of the FM was determined based on the morphological classification described by Bahşi et al (15).

This study aims to evaluate variations in the shape of the FM according to gender and age groups.

METHODS

The images in our study were retrospectively obtained from CT scans of the skull of 250 women and 250 men aged 20-69 years, stored in the Picture Archiving and Communication Systems (PACS) at the Department of Radiology, Faculty of Medicine, Düzce University. Radiological images in this study were acquired using a Siemens Somatom Definition AS 128-slice CT scanner with a tube voltage of 100 kV, tube current–time product of 49 mAs, scan time of 2 seconds, field of view (FOV) of 163 mm, and slice thickness of 0.6 mm. CT images acquired in this study were analyzed using Sectra Workstation IDS7 (Version 24.2.16.6006; © 2023 Sectra AB). Our study was approved by the Düzce University Non-Interventional Health Research Ethics Committee with decision number 2025/215. Individuals presenting any deformity affecting the anatomical structure of the cranial base, or with a history of surgical intervention or trauma to the skull, were excluded from the study. The CT images we selected randomly and retrospectively from the PACS were made orthogonal in the horizontal, sagittal and coronal planes using the 3D MPR (Multiplanar Reformat) tool. 3D images of the skull were obtained from the CT slices (Figure 1).

The individuals aged 20–69 included in the study were divided into five different age groups: 20–29, 30–39, 40–49, 50–59 and 60–69. Each age group consisted of 50 men and 50 women, for a total of 100 individuals per group, resulting in a total sample size of 500. The purpose of equal gender distribution was to prevent bias in the statistical analyses that could result from gender imbalance.

Turk J Clin Res. 2025;1(3):164-170
https://doi.org/10.63909/1453027

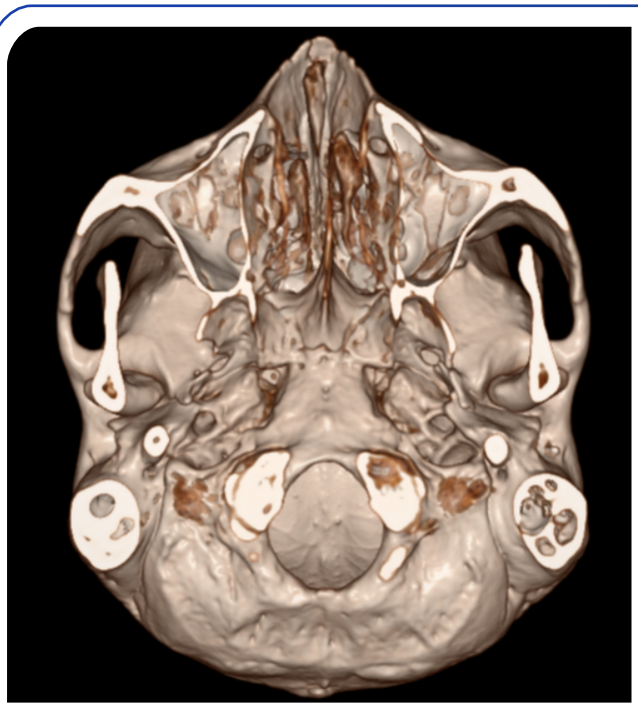

Figure 1. Three-dimensional image of the skull

Based on 3D images, the shape of the FM was classified as hexagonal, pentagonal, irregular, oval, tetragonal, octagonal, egg-shaped and round (Figure 2).

For the analysis of FM shape according to age and gender, IBM Statistical Package for the Social Sciences (SPSS) version 21 software was used. The relationship between morphological parameters and age and gender was evaluated using the Pearson Chi-Square test. In the analyses, $p<0.05$ was considered statistically significant.

RESULTS

By gender, in the classification of FM shapes, 37 men and 33 women had hexagonal shapes; 31 men and 33 women had pentagonal shapes; 16 men and 8 women had tetragonal shapes; 38 men and 47 women had irregular shapes; oval-shaped in 68 males and 83 females; octagonal-shaped in 1 male and 1 female; egg-shaped in 19 males and 16 females; and round-shaped in 40 males and 29 females. It was determined that 30.2% of the FM

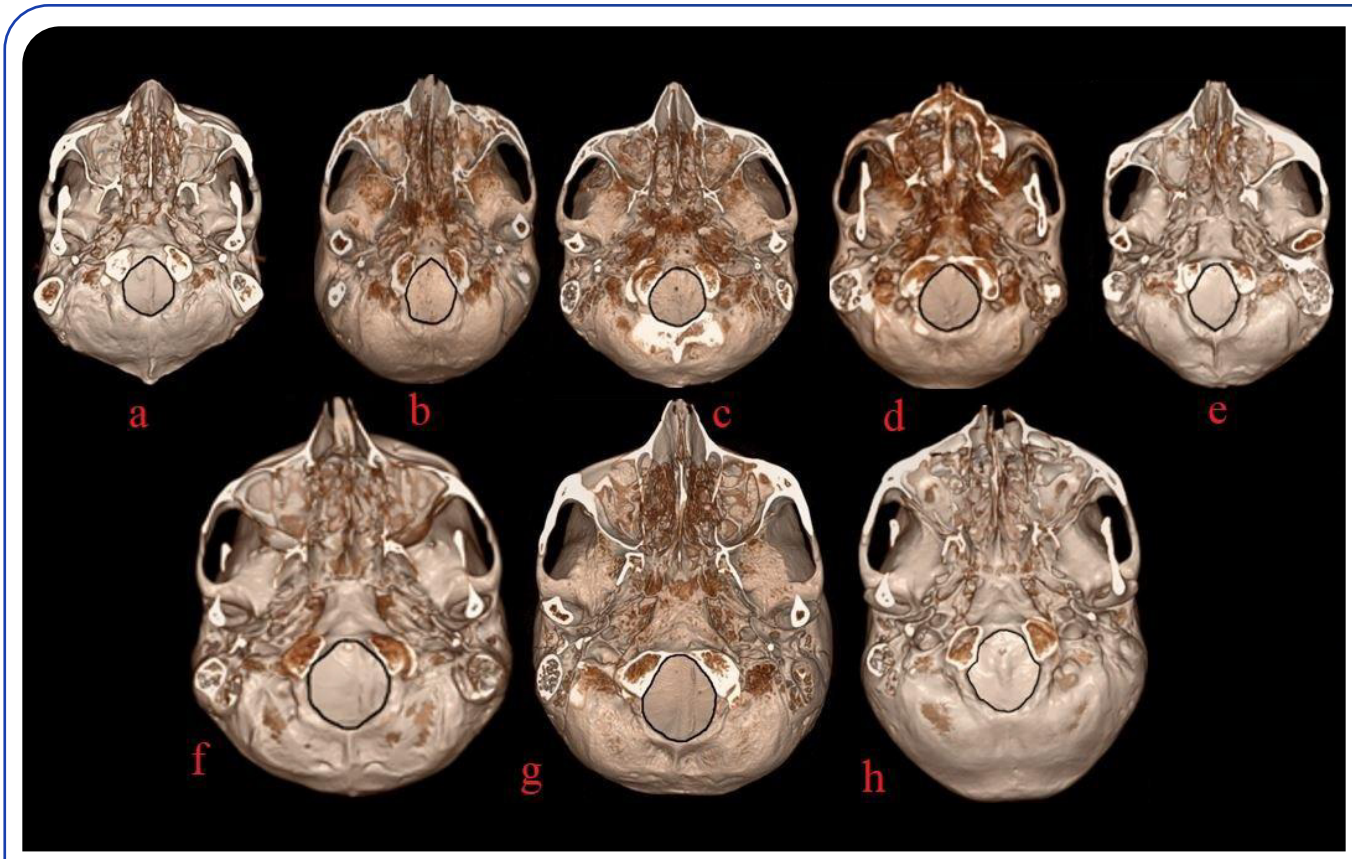

Figure 2. Shape of the foramen magnum (a: hexagonal, b: pentagonal, c: round, d: oval, e: tetragonal, f: octagonal, g: egg-shaped, h: irregular)

Turk J Clin Res. 2025;1(3):164-170
https://doi.org/10.63909/1453027

were oval-shaped. According to our literature review, we were the first to identify the octagonal shape of the FM. The relationship between gender and the shape of FM was evaluated using the Pearson Chi-Square test and the analysis revealed no statistically significant relationship between the two variables (p=0.387, Chi-Square=7.412) (Table 1). This result indicates that the shape of FM does not show a significant difference according to gender.

Table 1. Distribution of morphological types of the foramen magnum by gender

Figure	Male (n/%)	Female (n/%)	Total (n/%)
Hexagonal	37 (14.8%)	33 (13.2%)	70 (14.0%)
Pentagonal	31 (12.4%)	33 (13.2%)	64 (12.8%)
Tetragonal	16 (6.4%)	8 (3.2%)	24 (4.8%)
Irregular	38 (15.2%)	47 (18.8%)	85 (17.0%)
Oval	68 (27.2%)	83 (33.2%)	151 (30.2%)
Octagonal	1 (0.4%)	1 (0.4%)	2 (0.4%)
Egg-shape	19 (7.6%)	16 (6.4%)	35 (7.0%)
Round	40 (16.0%)	29 (11.6%)	69 (13.8%)
Total	250 (50%)	250 (50%)	500 (100%)
(p=0.387, χ^2=7.412)			

FM of 100 individuals in the 20-29, 30-39, 40-49, 50-59 and 60-69 age groups was evaluated in terms of shape. The relationship between age group and FM shape was evaluated using the Pearson Chi-Square test and the analysis revealed a statistically significant relationship between the variables (p=0.001, Chi-Square=68.04) (Table 2). This result indicates that FM shape shows significant differences according to age groups.

Table 2. Distribution of morphological types of the foramen magnum by age groups

Figure	20-29	20-39	40-49	50-59	60-69	Total
Hexagonal	22 (4.4%)	15 (3%)	9 (1.8%)	8 (1.6%)	16 (3.2%)	70 (14%)
Pentagonal	8 (1.6%)	8 (1.6%)	17 (3.4%)	17 (3.4%)	14 (6.8%)	64 (12.8%)
Tetragonal	11 (2.2%)	4 (0.8%)	5 (1%)	3 (0.6%)	1 (0.2%)	24 (4.8%)
Irregular	18 (3.6%)	19 (3.8%)	9 (3.8%)	10 (1.8%)	29 (5.8%)	85 (17%)
Oval	27 (5.4%)	33 (6.6%)	31 (6.2%)	38 (7.6%)	22 (4.4%)	151 (30.2%)
Octagonal	2 (0.4%)	0 (0%)	0 (0%)	0 (0%)	0 (0%)	2 (0.4%)
Egg-shape	5 (1%)	4 (0.8%)	10 (2%)	7 (1.4%)	9 (1.8%)	35 (7%)
Round	7 (1.4%)	17 (3.4%)	19 (3.8%)	17 (3.4%)	9 (1.8%)	69 (13.8%)
Total	100 (20%)	100 (20%)	100 (20%)	100 (20%)	100 (20%)	500 (100%)
(p=0.001, χ^2=68.04)						

DISCUSSION

By gender, the highest incidence of the FM shape was found to be 30.2% in the oval shape. The lowest rate by gender was found to be 0.4% in the octagonal shape. The highest incidence of the FM shape was determined to be oval in the 20-29, 30-39, 40-49 and 50-59 age groups. In the 60-69 age group, the highest rate of the FM shape was found to be irregular.

Determining the morphological and morphometric characteristics of the FM is important for identifying various abnormalities in the craniovertebral junction. This contributes to the planning of surgical procedures, the selection of the approach to be used and the minimization of operational risks (16,17). The morphological variability of FM has been fully characterized (17,18). The irregular shape of the FM may affect the instability of the craniovertebral junction (16).

Murshed et al. used CT images from 57 men and 53 women aged 18-80 in the Turkish population in their study and found that the most common form of FM was the round type, with a rate of 21.8% (19). Similarly,

Turk J Clin Res. 2025;1(3):164-170
https://doi.org/10.63909/1453027

Chethan et al. identified the round type as the most common FM shape, at a rate of 22.6%, in their analysis of 53 dry skulls from the Indian population (1). Bahşi et al. examined the shape of the FM using cone-beam CT images of 200 women and 200 men aged 18–65. The study found that the most common shape of the FM in both women and men was oval, while the least common shape was egg-shaped. No statistically significant relationship was found between the morphological characteristics of the FM and gender (15). Pires et al. classified the shape of the FM in 77 adult skulls of unknown sex from the Brazilian population. The most common shape of FM in their study was oval, accounting for 53.24% (20). Mishra et al. also studied 71 skulls from the Lucknow population and found that the FM shape was oval in 37.8% of them (21). Using 53 dry skulls of unknown age and sex from the Chennai population, Fathima and Babu classified the FM shapes as 26% oval, 36% egg-shaped, 13% round, 4% pentagonal, and 21% hexagonal (22). Ilhan et al. obtained the following results from a sample of 100 dry skulls of unknown gender and age in the Turkish population: 24% tetragonal, 22% irregular, 21% hexagonal, 12% egg-shaped, 10% oval, 6% round and 5% pentagonal (23). Sharma et al. examined 62 dry skull samples from an Rajasthan population FM as 35.48% oval, 17.74% round, 19.35% egg-shaped, 11.29% tetragonal, 1.61% pentagonal, 9.68% hexagonal and 4.84% irregular (24). In our study, eight types were determined as egg-shaped, oval, irregular, pentagonal, hexagonal, octagonal, irregular and round. FM shape was found to be oval with the highest rate of 30.2% according to gender, while octagonal had the lowest rate of 0.4%. The variability of the shape characteristics of FM in different population samples reveals that, in addition to the methodology used, the ethnic origins of individuals and the diversity in sample size are also among the determining factors.

Akay et al. performed a morphological classification of the FM using cone-beam CT images of 88 men and 102 women aged 17–81 from the Turkish population. The shape of the FM according to gender was found to be round in women at the highest rate, while it was hexagonal in men. The study found no statistically significant difference between the FM shape and gender; it was noted that this morphological feature does not exhibit sexual dimorphism (25). Lashin et al. performed a morphological classification of FM using CT images from 200 individuals (100 males, 100 females) aged 18–88 years in Egypt. They found no statistically significant association between gender and FM shape in their study (26). Burdan et al. examined the shape distribution of the FM in a study conducted on 142 male and 171 female individuals aged 20–30 in the Eastern European Caucasian population; they found that the wide oval shape was the most common, occurring in 36.62% of males and 39.18% of females. However, they did not find a statistically significant relationship between shape and gender (14). Moodley et al. examined CT images from 93 men and 57 women and found that the most common shape in men was egg-shaped at a rate of 12%, while in women it was egg-shaped at a rate of 8.67%. However, they did not find a statistically significant difference between shape and gender (11). In our study, statistical analyses performed on data from the sample population revealed no statistically significant relationship between FM shape and gender (p=0.387). Studies in the literature support our finding that FM shape is not statistically significantly related to gender.

Moodley et al. conducted a morphological analysis of FM on a total of 150 individuals, with 50 individuals in each age group: 1–12 (children), 13–17 (adolescents) and 18–25 (adults). In the 1–12 age group, the most common shape of the FM was egg-shaped at 8.67%, while the least common shape was oval at 0.67%. In the 13–17 age group, the most common shape was again egg-shaped at 10%, while oval and irregular shapes were the least common at 0%. In the 18–25 age group, the highest rate was 7.33% for hexagonal shape and the lowest rate was 0.67% for oval shape. The study reported statistically significant differences in FM shapes according to age groups (11). In our study, when examining the distribution of FM shapes by age group, the most common shape among the 50 individuals in the 20–29 age group was oval at 5.4%, while the least common was octagonal at 0.4%. In the 30–39 age group, the oval shape was the most common, found in 6.6% of individuals, while the octagonal shape was not observed. Similarly, in the 50 individuals in the 40–49 age group, the oval shape was the most common at 6.2%; the octagonal shape was again not observed. In the 50–59 age group, the oval shape was the most frequently detected shape at a rate of 7.6% and the octagonal shape was not observed in this group either. In the 60–69 age group, the most common shape was determined to be

Turk J Clin Res. 2025;1(3):164-170
https://doi.org/10.63909/1453027

irregular at a rate of 5.8% and the octagonal shape was not detected in this age group either. Furthermore, our study found statistically significant differences in FM shapes according to age groups (p=0.001). This finding is similar to the study by Moodley et al. who evaluated the distribution of FM shapes according to age groups. While the oval shape was observed at the lowest rate among age groups in the study by Moodley et al. the oval shape was determined to be the most common in the 20–59 age groups in our study. This difference may be attributed to variations in the populations, age group ranges and sample sizes used in the studies.

One limitation of our study is that FM morphological classification is partly interpretative, due to the lack of standardized criteria. Moreover, studying only a specific geographical population limits the generalizability of the findings. Additionally, the small sample size across age groups made it difficult to fully demonstrate variations in FM shape across age groups. It is believed that increasing the sample size across age groups could increase overall population-specific accuracy.

While studies classifying the shape of FM based on gender are common, studies addressing shape changes related to age groups are quite limited in number. We believe that morphological analysis of FM in different populations, genders and age groups will help identification studies in anthropology and forensic medicine.

CONCLUSION

In this study, the shape of the FM in healthy individuals was evaluated morphologically. It was found that the shape of the FM did not show sexual dimorphism in terms of gender but showed statistically significant differences according to age groups. We believe that determining the shape of the FM will make important contributions, especially in the planning of surgical interventions targeting the craniovertebral junction.

Acknowledgement: We would like to thank all healthcare professionals in the Department of Radiology at Düzce University Faculty of Medicine. This study was presented as an oral presentation at the 12th International "ACHARAKA" Congress on Medicine, Nursing, Midwifery and Health Sciences.

Ethical Approval: Our study was approved by the Düzce University Non-Interventional Health Research Ethics Committee (Date: 25.08.2025; Decision No: 2025/215).

Author Contributions: Idea/Concept: H.Y., S.C., Y.S., O.O.; Design: H.Y., S.C., Y.S., O.O.; Supervision: H.Y., S.C., Y.S., O.O.; Resources: H.Y., S.C., Y.S., O.O.; Materials: H.Y., S.C., Y.S., O.O.; Data Collection and/or Processing: H.Y., S.C., Y.S., O.O.; Analysis and/or Interpretation: H.Y., S.C., Y.S., O.O.; Literature Review: H.Y., S.C., Y.S., O.O.; Written H.Y., S.C., Y.S., O.O.; Critical Reviews: H.Y., S.C., Y.S., O.O.

Conflict of Interest: The authors declare no conflict of interest.

Financial Disclosure: The authors declared that this study has received no financial support.

REFERENCES

1. Chethan P, Prakash KG, Murlimanju BV, Prashanth KU, Prabhu LV, Saralaya VV, et al. Morphological analysis and morphometry of the foramen magnum: an anatomical investigation. Turk Neurosurg. 2012;22(4).416-9.
2. Singh D, Patnaik P, Gupta N. Morphology and morphometric analysis of the foramen magnum in dried adult skulls in North Indian region. Int J Health Sci Res. 2019;9(4):36–42.
3. Arifoğlu Y. Her Yönüyle Anatomi. 4th ed. İstanbul: İstanbul Tıp Kitabevi; 2024:70.
4. Zdilla MJ, Russell ML, Bliss KN, Mangus KR, Koons AW. The size and shape of the foramen magnum in man. J Craniovertebr Junction Spine. 2017;8(3):205–21.
5. Toneva D, Nikolova S, Harizanov S, Georgiev I, Zlatareva D, Hadjidekov V, et al. Sex estimation by size and shape of foramen magnum based on CT imaging. Leg Med. 2018;35:50–60.
6. Uthman AT, Al-Rawi NH, Al-Timimi JF. Evaluation of foramen magnum in gender determination using helical CT scanning. Dentomaxillofac Radiol. 2012;41(3):197–202.
7. Vinutha SP, Suresh V, Shubha R. Discriminant function analysis of foramen magnum variables in South Indian population: a study of computerised tomographic images. Anat Res Int. 2018;2018(1):2056291.
8. Govsa F, Ozer MA, Celik S, Ozmutaf NM. Three-dimensional anatomic landmarks of the foramen magnum for the craniovertebral junction. J Craniofac Surg. 2011;22(3):1073–6.
9. Natsis K, Piagkou M, Skotsimara G, Piagkos G, Skandalakis P. A morphometric anatomical and comparative study of the foramen magnum region in a Greek population. Surg Radiol Anat. 2013;35(10):925–34.

Turk J Clin Res. 2025;1(3):164-170
https://doi.org/10.63909/1453027

10. Moodley M, Berry CR, Lazarus L, Satyapal KS. The morphometry and morphology of the foramen magnum ın age and sex determination within the south african black population utilizing Computer Tomography (CT) scans. Int J Morphol. 2019;37(1):251–7.
11. Michiue T, Hishmat AM, Oritani S, Miyamoto K, Amin MF, Ishikawa T, et al. Virtual computed tomography morphometry of the patella for estimation of sex using postmortem Japanese adult data in forensic identification. Forensic Sci Int. 2018;285:206.e1-206.e6.
12. Zhang M. Forensic imaging: a powerful tool in modern forensic investigation. Forensic Sci Res. 2022;7(3):385–92.
13. Burdan F, Szumiło J, Walocha J, Klepacz L, Madej B, Dworzański W, et al. Morphology of the foramen magnum in young Eastern-European adults. Folia Morphol (Warsz). 2012;71(4):205–16.
14. Bahşi İ, Adanır SS, Orhan M, Kervancıoğlu P, Büyükbeşe ZS, Yalçın ED, et al. Anatomical evaluation of the foramen magnum on cone-beam computed tomography images and review of literature. Cureus. 2021;13(11).e19385.
15. Singh G, Talwar I. Morphometric analysis of foramen magnum in human skull for sex determination. Hum Bio Rev. 2(1):29-41.
16. Sharma DK, Mehra S. Foramen magnum: A morphological and morphometric study in dried human skull bones of Rajasthan population and its surgical importance. J Mahatma Gandhi Univ Med Sci Technol. 2016;3(2):41–9.
17. Vinutha SP, Suresh V, Shubha R. Discriminant function analysis of foramen magnum variables in South Indian population: a study of computerised tomographic images. Anat Res Int. 2018;2018(1):2056291.
18. Murshed KA, Çiçekcibaşi AE, Tuncer I. Morphometric evaluation of the foramen magnum and variations in its shape: a study on computerized tomographic images of normal adults. Turk J Med Sci. 2003;33(5):301–6.
19. Pires LAS, Teixeira ÁR, Leite TFO, Babinski MA, Chagas CAA. Morphometric aspects of the foramen magnum and the orbit in Brazilian dry skulls. Int J Med Res Health Sci. 2016;5(4):34–42.
20. Mishra AK, Pandey SB, Yadav CK, Haque M, Chandra N. Morphometric study of foramen magnum of skull ın population of uttar pradesh. Int J Anat Res. 2018;6(2):5186-90.
21. Fathima F, Babu KY. Evaluating the shape of foramen magnum and overlapping of occipital condyle on the foramen. Int J Sci Res. 2016;5(9):1078–82.
22. Ilhan P, Kayhan B, Erturk M, Sengul G. Morphological analysis of occipital condyles and foramen magnum as a guide for lateral surgical approaches. MOJ Anat Physiol. 2017;3(6):188–94.
23. Sharma S, Mathur S, Joshi P, Gupta UK. Morphological and morphometric study of foramen magnum in dried human skull bones of North-West Indian region. Int J Approx Reason. 2020;8:7777–81.
24. Akay G, Güngör K, Peker I. Morphometric analysis of the foramen magnum using cone beam computed tomography. Turk J Med Sci. 2017;47(6):1715–22.
25. Lashin HI, Eldeeb BS, Ghonem MM. Sex identification from foramen magnum using computed tomography scanning in a sample of Egyptian population. J Forensic Radiol Imaging. 2019;19:100341.