Turkish Journal of Clinical Research

Turk J Clin Res. 2025;1(1):29-33
https://doi.org/10.63909/1453012

RESEARCH ARTICLE

Clinical signs, symptoms and surgical outcomes of patients with lumbosacral nerve root anomalies

Lumbosakral sinir kökü anomalili hastaların klinik bulguları, belirtileri ve cerrahi sonuçları

Tugba MORALI GULER[1], Hikmet DEMIRKOL[1], Ilker ALACA[2], Ismail KARA[3]

[1]Private Medikar Hospital, Neurosurgery Unit, Karabük, Türkiye
[2]Bülent Ecevit University, Faculty of Medicine, Department of Neurosurgery, Zonguldak, Türkiye
[3]Karabük University Training and Research Hospital, Specialist Doctor, Karabük, Türkiye

Abstract

Aim: To raise awareness of lumbosacral nerve root anomalies, to avoid neurological deficits caused by nerve injury during surgery in patients with these anomalies.

Methods: Age, sex, symptoms at presentation, neurological examination, MRI findings, the level and side of the lumbosacral nerve root anomalies, complications and surgical outcomes of patients with lumbosacral nerve root abnormalities were documented.

Results: Among 1924 patients, nerve root anomalies were detected in 13 patients (mean age, 43 years; female/male ratio, 9/4). The incidence was 0.68%. All cases had radicular leg pain and 11 had neurological deficits preoperatively. Lumbosacral nerve root anomalies were observed at the level of L4-5 and on the left side in 3 (23.10%) patients, at the level of L5-S1 on the left side in 5 (38.45%) patients and at the level of L5-S1 on the right side in 5 (38.45%) patients. In 2 (15.38%) patients, there was a dural injury occurred but without neurological deficits. Postoperative neuropathic pain was present in 5 (38.50%) of the patients.

Conclusion: Although lumbosacral nerve root anomalies are rarely observed, nerve root injuries can occur perioperatively in these patients. In addition, pain relief is harder to achieve and postoperative neuropathic symptoms are more commonly observed in these patients.

Keywords: Spinal nerve roots, radiculopathy, low back pain, mechanical, neurologic deficits.

Özet

Amaç: Lumbosakral sinir kökü anomalisi olan hastalarda cerrahi sırasında sinir hasarına bağlı nörolojk defisitlerin önlenmesi için bu anomalilere ilişkin farkındalığı arttırmak

Yöntemler: Lumbosakral sinir kökü anomalili hastaların yaş, cinsiyet, başvuru esnasındaki semptomları, nörolojik muayane, MR bulguları, lumbpsakral sinir kökü anomalisi seviyesi ve tarafı, komplikasyonlar ve cerrahi sonuçlar dökümente edildi.

Bulgular: 1924 hasta içinde 13 hastada (ortalama yaş 43; kadın/erkek oranı: 9/4) sinir kökü anomalisi saptandı. Lumbosakral sinir kökü anomalisi 3 (%23.10) hastada L4-5 seviyesinde ve sol tarafta, 5 hastada (%38,45) L5-S1 düzeyinde ve sol tarafta, 5 hastada (% 38,45) L5-S1 düzeyinde ve sağ tarafta gözlemlendi. 2 hastada (%15,38) nörolojik deficit olmaksızın dural hasar oluştu. Postoperatif nörolojik ağrı hastaların 5'inde (% 38,45) mevcuttu.

Sonuç: Lumbosakral sinir kökü anomalileri nadir görülmekle birlikte bu hastalarda perioperative dönemde sinir kökü yaralanmaları görülebilmektedir. Ek olarak ağrı kontrolünü sağlamak da daha güçtür ve nöropatik semptomlar bu hastalarda daha sık olarak görülmektedir.

Anahtar Kelimeler: Spinal sinir kökleri, radikülopati, bel ağrısı, mekanik, nörolojik deficit.

INTRODUCTION

Lumbosacral nerve root anomalies (LNRAs) have been characterised in detail. Zagnoni first described these anomalies mainly based on anatomical dissections (1). According to different reports, the incidence of LNRAs is 0.3–30% (2-4). These anomalies are usually unilateral and left sided. Moreover, 50% of LNRAs are observed at the level of L5-S1 (3,5,6). Canon et al. performed the first classification of LNRAs (7); since then, there have been others (5,8-10). Although the embryological cause of LNRAs remains unknown, abnormal root migrations could be one possible mechanism (2,11).

Corresponding Author: Tugba MORALI GULER tugbamorali@yahoo.com
Cite as: Morali Guler T, Demirkol H, Alaca I, Kara I. Clinical signs, symptoms and surgical outcomes of patients with lumbosacral nerve root anomalies. Turk J Clin Res. 2025;1(1):29-33

Content of this journal is licensed under a Creative Commons Attribution-NonCommercial-NonDerivatives 4.0 International License

Received: 27 Apr 2025 | **Accepted:** 28 May 2025 | **Published:** 30 May 2025

Turk J Clin Res. 2025;1(1):29-33
https://doi.org/10.63909/1453012

LNRAs are rarely observed pathologies. However, nerve root injuries and neurological deficits can occur after surgery if LNRAs remain unnoticed. Even if they are detected during surgery, pain relief is more difficult to achieve after simple microdiscectomy and neuropathic symptoms are more commonly observed postoperatively (1,4,8,12). Here, we describe common LNRA characteristics among 13 patients to increase awareness of these anomalies particularly with respect to spinal surgery.

METHODS

Patients undergoing surgery from lumbar-disc herniation over a 6-year-period between 01.06.2015-01.06.2021 in the Karabük University Training and Research Hospital were included in the study. Before microdiscectomy we performed a lumbar hemilaminectomy and medial facetectomy and then removed the ligamentum flavum in all patients with LNRA. Patients with pathologies such as tumours or trauma were excluded from the study.

All LNRAs were detected intraoperatively and none of the patients had been diagnosed through preoperative imaging. Patient characteristics such as age, sex, symptoms at presentation, neurological examination and MRI findings, LNRA level and side, surgical techniques, complications and surgical outcomes were documented for all patients with LNRA. In addition, LNRAs were classified according to the relationship between the disc localisation and LNRA.

Approval for this study was received from the Ethics Committee of Karabuk University Faculty of Medicine (No: E-77192459-050.99-209323, Decision Number: 2023/1226)

Statistical Analysis

The conformity of the patients' age to the normal distribution was examined using the Shapiro-Wilk test. Age was presented using the median, minimum and maximum values, categorical variables were reported together with the frequency and corresponding percentage values. The chi-square test determined whether LNRA levels differed depending on the side. Analyses were performed using SPSS (IBM Corp. Released 2019. IBM SPSS Statistics for Windows, Version 26.0. Armonk, NY: IBM Corp.).

RESULTS

A total of 1924 patients were included in the study. LNRAs were detected in 13 patients (incidence, 0.68%).

The mean age of the patients was 43 years (minimum: 29 years, maximum: 58 years). There were more affected women than men (female, 9 [69.20%]; male, 4 [30.80%]).

All cases were admitted to the hospital for a complaint of radicular leg pain and 11 (84.61%) patients showed deficits in the neurological examination. LNRAs were observed at L4-5 on the left side in 3 (23.10%) patients, at L5-S1 on the left side in 5 (38.45%) patients and at L5-S1 on the right side in 5 (38.45%) patients. Table 1 shows detailed information of all cases. There was no significant difference in LNRA levels depending on the affected side (p=0.231).

Table 1. The detailed information of all cases

Gender	Age	Neurological Deficit	Level	Side
F	56	+	L5-S1	L
F	43	+	L5-S1	L
M	43	+	L5-S1	R
F	49	+	L5-S1	R
F	42	+	L4-L5	L
F	56	+	L5-S1	R
F	35	+	L5-S1	L
F	29	+	L5-S1	L
F	58	-	L5-S1	R
F	50	+	L5-S1	R
M	40	-	L5-S1	L
M	40	+	L4-L5	L
M	53	+	L4-L5	L

F: Female, M: Male, L: Left, R: Right

According to Neidre and MacNab's classification, 7 (53.84%) patients were classified as Type 1 and 6 (46.16%) patients as Type 2. We did not detect a Type 3 anomaly in any patient. For Kayacı et al.'s classification, 5 (38.50%) patients belonged in Group A, 5 (38.50%) in Group B and 3 (23.10%) in Group C.

For better and extended exposure, a partial facetectomy

Turk J Clin Res. 2025;1(1):29-33
https://doi.org/10.63909/1453012

and a wide foraminotomy were performed in addition to routine hemilaminectomy in all cases (Figure 1 and 2). In 2 (15.38%) patients, the dura of the laterally located nerve root was injured but no neurological deficit was observed postoperatively. Neuropathic pain was observed in 5 (38.50%) patients after surgery treated with pregabalin postoperatively. Radicular pain was still present in 3 (23.10%) patients after surgery, which was not relieved by medication, so these patients were reoperated (one patient at 10 days, another at 1 month and the last patient at 2 years after the first surgery).

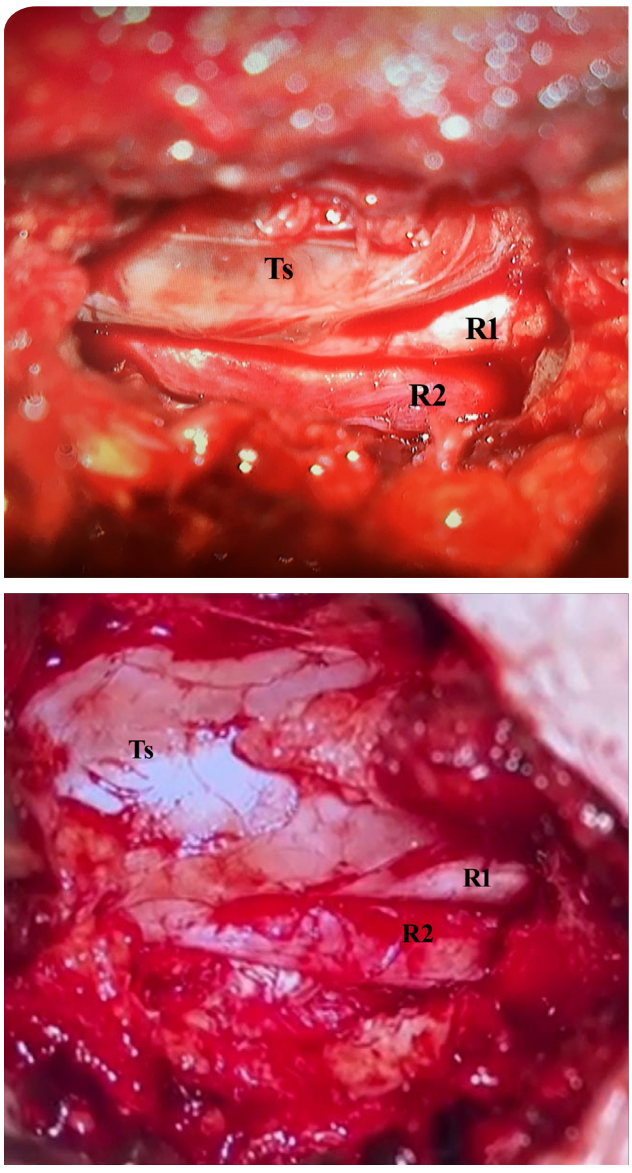

Figure 1. A partial facetectomy and a wide foraminotomy were performed in addition to routine hemilaminectomy. **Ts:** Tecal sac, **R1:** Root 1, **R2:** Root 2

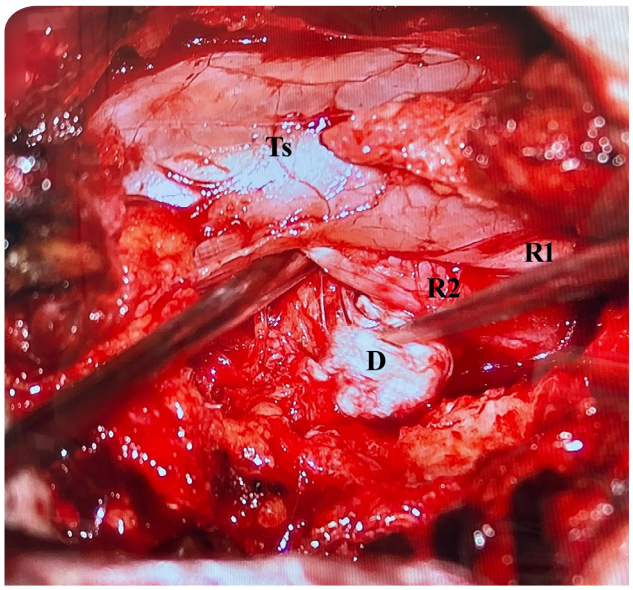

Figure 2. **A-B** A thin medially located root (R1) and a larger laterally located root (R2) and the disc fragment located under the laterally located root are seen. **Ts:** Tecal sac, **R1:** Root 1, **R2:** Root 2, **D:** Disc fragment

DISCUSSION

A different incidence of LNRA were declared in different series in the literature. White et al. explained the incidence of the conjoined nerve root anomaly as 1.3% (12). According to Can et al. the conjoint nerve root anomaly was observed in 3.4% of 612 patients (4). On the other hand, Kadish and Simmons dissected 100 cadaveric specimens and the overall incidence of the nerve root anomalies was detected as 14%. As expected, the incidences are high in cadaveric series. In our study the incidence of LNRA was 0.68%.

Canon et al. found no significant sex differences in the incidence of LNRA (7). However, in Pamir et al.'s study, 2 (17%) patients were male and 10 (83%) patients were female (2). Similarly, in our study we observed a female predisposition, 9 (69.20%) patients were female and 4 (30.80%) patients were male.

Canon et al. who first classified LRNAs, described three types which can be observed during lumbar-disc surgery, conjoint root anomaly, transversal root anomaly and anastomotic roots. Accordingly, conjoined root anomalies consist of two adjacent nerve roots from a common origin after a short or a long joined course, which

Turk J Clin Res. 2025;1(1):29-33
https://doi.org/10.63909/1453012

separate leaving the spinal canal from different foramens, or continue being joined leaving the canal from the same foramen (7). The transversal root usually originates at a lower level than normal and follows a transverse course from the origin to the foramen (7). Finally, the anatomosis between roots follows an oblique course, as the upper nerve root branches into the lower one (7).

Neidre and Macnab's classification, the most common classification system (8), classified conjoined nerve roots in three main groups: Type 1A for nerve roots arising from a common dural sheath, Type 1B for nerve roots almost conjoint but angled, like a cervical nerve root. In Type 2, the nerve roots exit through one foramen (Type 2A, if one root canal remains unoccupied; Type 2B, if every foramen contains nerve roots but one foramen contains two separate nerve roots). The last, Type 3 is a kind of anastomosis that connects adjacent nerve roots through a connecting root (13). Pamir et al. reported 12 LRNA cases, according to Nedire and Macnab, most patients had a Type I or Type II (42% and 33%, respectively), only a single case (8%) had a Type 3 anomaly and two cases had combined anomalies (2). In our study, according to Neidre and MacNab Classification, 7 (53.80%) patients had a Type 1 and 6 (46.20%) a Type 2 anomaly; we did not detect any Type 3 anomaly.

Kayacı et al.'s classification is based on the relationship between the disc and the LRNA (3). In Group A, the herniated disc is located between the medially located nerve root and the dura, in Group B, the herniated disc is located between the two nerve roots and in Group C, the herniated disc is found between the laterally localised nerve root and the facet or lateral recess. In our study, 5 (38.50%) anomalies were Group A, 5 (38.50%) Group B and 3 (23.10%) Group C.

Nerve root anomalies most commonly affect the L5 and S1 roots (approximately 50% of all nerve root anomalies) and most occur on the left side, usually unilaterally (3,5,6,14,15). In our study, LRNAs were observed on the left L4-5 in 3 (23.10%) patients, on the left L5-S1 in 5 (38.50%) patients and on the right L5-S1 in 5 (38.50%) patients.

There is a higher incidence of failure of pain relief after lumbar-disc surgery in patients with a conjoined root anomaly compared to the normal population (2,5,7,12). Kadish and Simmons explained two major reasons for this finding. First, the anomaly itself can cause pain or the anomalous root occupies most of the space in the vertebral canal, which can cause the symptoms even with a little bulging or oedema (5). Pamir et al. emphasised that a standard surgical technique (hemilaminectomy and discectomy) could not provide sufficient decompression in these cases, recommending a more extended surgical exposure and techniques such as laminectomy or facetectomy with pedicle excision (2). In addition, Pamir et al. stated the importance of wide decompression and LRNA recognition to avoid excessive traction and to consider LRNA presence in case of 'failed back syndrome' (2). On the other hand, Kayacı et al. recommended medial facetectomy, removal of the ligamentum flavum and microdiscectomy as surgical intervention (3). In our study, before microdiscectomy we performed a lumbar hemilaminectomy and medial facetectomy to avoid excessive compression and root traction and removed the ligamentum flavum to relieve the spinal stenosis caused by the root anomaly and this was part of our routine procedure in patients with LNRA. Discectomy can also be frequently performed not easily in these cases as the conjoint roots block the vision. In 2 (15.40%) patients, accidental dural tear occurred without postoperative neurological deficits.

Can et al. measured the root thicknesses of the conjoined roots, finding that the thicker the root or the higher the root exit angle, the more commonly observed neuropathy and root injury due to excessive retraction (4). In our study, the incidence of postoperative severe neuropathic complaints requiring medical treatment was 38.50%.

CONCLUSION

LNRAs such as conjoint roots can be easily missed in preoperative magnetic resonance images as these anomalies are observed in coronal sections which are not routinely used in daily practice as in our hospital that lumbar spinal MRIs have only axial and sagittal sections. Thus, many cases of LNRA are detected during surgery. Perhaps with technological developments all these anomalies will be detected preoperatively in future. In daily practice to avoid iatrogenic nerve injury and provide sufficient pain relief, it is important to consider the possibility of LNRAs.

Turk J Clin Res. 2025;1(1):29-33
https://doi.org/10.63909/1453012

Acknowledgement: None.

Ethical Approval: Approval for this study was received from the Ethics Committee of Karabuk University Faculty of Medicine (No: E-77192459-050.99-209323, Decision Number: 2023/1226).

Author Contributions: Idea/Concept: T.M.G., H.D.; Design: T.M.G., H.D., İ.A.; Supervision: T.M.G., İ.K.; Resources: T.M.G., H.D., İ.A., İ.K.; Materials: T.M.G., H.D., İ.A.; Data Collection and/or Processing: T.M.G., H.D., İ.A.; Analysis and/or Interpretation: T.M.G.; Literature Review: T.M.G., İ.A., İ.K.; Written: T.M.G.; Critical Reviews: T.M.G., H.D., İ.A., İ.K.

Conflict of Interest: There is no conflict of interest between authors.

Financial Disclosure: There is no financial support or funding for this study.

References

1. Zagnoni C. Reperto di un tipo non conosciuto di anastomosi nervosa delle radici spinali. Atti Soc Med Chir Padova. 1949;27:48-52.
2. Pamir MN, Özek MM, Özer AF, Erzen C. Surgical considerations in patients with lumbar spinal root anomalies. Paraplegia. 1992;30(5):370-5.
3. Kayacı S, Köksal V, Çağlar Ş. The relationship of lumbosacral root anomalies with a herniated disc fragment. Turk Neurosurg. 2014;24(1):15-9.
4. Can H, Kircelli A, Kavadar G, Civelek E, Cansever T, Aydoseli A et al. Lumbosacral Conjoined root anomaly: anatomical considerations of exiting angles and root thickness. Turk Neurosurg. 2017;27(4):617-22.
5. Kadish LJ, Simmons EH. Anomalies of the lumbosacral nerve roots. An anatomical investigation and myelographic study. J Bone Joint Surg Br. 1984;66(3):411-6.
6. Artico M, Franchitto S, Carloia S, Piancentini S, Ferretti G, Dazzi M et al. Conjoined lumbosacral nerve roots: observations on three cases and review of the literature. Neurocirugia (Astur). 2006;17(1):54-9.
7. Cannon BW, Hunter SE, Picaza JA. Nerve-root anomalies in lumbar disc surgery. Journal Neurosurg. 1961;19(3):208-14.
8. Burke SM, Safain MG, Kryzanski J, Riesenburger RI. Nerve root anomalies: implications for transforaminal lumbar interbody fusion surgery and a review of the Neidre and Macnab classification system. Neurosurg Focus, 2013;35(2):E9.
9. Postacchini F, Urso S, Ferro L. Lumbosacral nerve root anomalies. J Bone Joint Surg Am. 1982;64:721-9
10. Kikuchi S, Hasue M, Nishiyama K, Ito T. Anatomic and clinical studies of radicular symptoms. Spine (Phila Pa 1976). 1984;9(1):23-30
11. Trimba R, Spivak JM, Bendo JA. Conjoined nerve roots of the lumbar spine. Spine J. 2012;12(6):515-24.
12. White JG, Strait TA, Binkley JR, Hunter SE. Surgical treatment of 63 cases of conjoined nerve roots. J Neurosurg. 1982;56(1):114-7.
13. Neidre A, MacNab I. Anomalies of the lumbosacral nerve roots. Review of 16 cases and classification. Spine (Phila Pa 1976). 1983;8(3):294-9.
14. Jokhi VH, Ponde SV, Sonawane C, Bansal SS, Chavhan A. Conjoint lumbosacral nerve root-a case report. J Orthop Case Rep. 2015;5(4):14-6.
15. Yılmaz T, Turan Y, Gülşen İ, Dalbayrak S. Co-occurrence of lumbar spondylolysis and lumbar disc herniation with lumbosacral nerve root anomaly. J Craniovertebr Junction Spine, 2014;5(2):99-101.