Turkish Journal of Clinical Research

Turk J Clin Res. 2025;1(1):21-28
https://doi.org/10.63909/1453011

RESEARCH ARTICLE

A 30-year single-center experience with intracranial hydatid cysts: Clinical and surgical outcomes of 50 cases

İntrakranial hidatik kistleriyle 30 yıllık tek merkezli deneyim: 50 olgunun klinik ve cerrahi sonuçları

Yakup CAGLAROGLU[1], Muhammet ELVEREN[1], Ufuk TEMTEK[1], Caner Fahrettin KARA[2]

[1]Erzurum Regional Training and Research Hospital, Medical Faculty of University of Health Sciences, Department of Neurosurgery, Erzurum, Türkiye
[2]Giresun Training and Research Hospital, Department of Neurosurgery, Giresun, Türkiye

Abstract

Aim: Intracranial hydatid cyst is a rare zoonotic disease that should be considered in the differential diagnosis of intracranial space-occupying lesions in endemic regions. This study aims to evaluate and compare the clinical and radiological characteristics, surgical approaches, and outcomes of patients treated for intracranial hydatid cysts over a 30-year period in a single center.

Methods: Fifty patients operated on between 1993 and 2023 were retrospectively evaluated and divided into two cohorts: Group A (1993–2003) and Group B (2003–2023). All patients underwent preoperative neurological and radiological assessment, including CT and MRI. Diagnosis was supported by serological tests and systemic imaging. Surgery was performed using the Dowling technique, and all patients received albendazole treatment pre- and postoperatively. Statistical analysis was conducted using chi-square and Student's t-tests.

Results: The mean age significantly decreased from 32.0±13.6 years (Group A) to 22.3±14.2 years (Group B) (p=0.018). Headache was the most common presenting symptom. In Group B, multiple cysts were observed in 31.3%, and mortality occurred in 12.5%. Radiologically, cysts appeared as well-circumscribed, non-enhancing lesions, typically hypodense on CT and hyperintense on T2-weighted MRI. Two patients had alveolar-type cysts with characteristic findings.

Conclusion: Intracranial hydatid cyst remains a significant diagnosis in endemic regions, especially in children and young adults. MRI plays a crucial role in detection. Intact surgical removal using the Dowling technique, combined with albendazole therapy, improves outcomes. Continued public health efforts and early diagnosis remain key to reducing disease burden.

Keywords: Hydatid cyst, intracranial echinococcosis, dowling technique, albendazole, surgical outcomes.

Özet

Amaç: İntrakraniyal hidatik kist, endemik bölgelerde intrakraniyal yer kaplayıcı lezyonların ayırıcı tanısında mutlaka göz önünde bulundurulması gereken nadir bir zoonotik hastalıktır. Bu çalışmada, tek merkezde 30 yıllık süreçte intrakraniyal hidatik kist nedeniyle tedavi edilen hastaların klinik ve radyolojik özellikleri, cerrahi yaklaşımları ve tedavi sonuçlarının değerlendirilmesi ve karşılaştırılması amaçlanmıştır.

Yöntemler: 1993–2023 yılları arasında ameliyat edilen 50 hasta retrospektif olarak değerlendirilmiş ve ameliyat yıllarına göre iki gruba ayrılmıştır: Grup A (1993–2003) ve Grup B (2003–2023). Tüm hastalara preoperatif nörolojik muayene ile birlikte BT ve MRG dahil olmak üzere görüntüleme tetkikleri uygulanmıştır. Tanı, serolojik testler ve sistemik görüntülemelerle desteklenmiştir. Cerrahi müdahalelerde öncelikli olarak Dowling tekniği kullanılmış, tüm hastalara pre- ve postoperatif dönemde albendazol tedavisi uygulanmıştır. Veriler ki-kare ve Student's t-testi ile istatistiksel olarak analiz edilmiştir.

Bulgular: Grup A'da ortalama yaş 32,0±13,6 yıl iken, Grup B'de bu değer 22,3±14,2 yıl olup, fark istatistiksel olarak anlamlı bulunmuştur (p=0,018). En sık başvuru semptomu baş ağrısıydı. Grup B'de hastaların %31,3'ünde multipl kist saptanmış, %12,5'inde mortalite görülmüştür. Görüntüleme bulgularında, kistler tipik olarak BT'de hipodens, MRG'de T2-ağırlıklı sekanslarda hiperintens, sınırlı ve kontrast tutmayan lezyonlar şeklinde izlenmiştir. İki hastada karakteristik özellikler taşıyan alveolar tip kist tespit edilmiştir.

Sonuç: İntrakraniyal hidatik kist, özellikle çocuk ve genç erişkin popülasyonda, endemik bölgelerde ayırıcı tanıda önemini koruyan bir hastalıktır. Tanıda MRG temel rol oynamakta, kistin sağlam şekilde çıkarılması ve albendazol tedavisi ile sonuçlar iyileşmektedir. Hastalık yükünü azaltmak için erken tanı olanaklarının artırılması ve halk sağlığı önlemlerinin sürdürülmesi önem taşımaktadır.

Anahtar Kelimeler: Hidatik kist, intrakranial ekinokokkozis, dowling tekniği, albendazol, cerrahi sonuçlar.

INTRODUCTION

Hydatid disease is a zoonotic infection that originates from the larval forms of cestodes within the Echinococcus genus, and it predominantly affects populations residing in areas with frequent interaction with domestic or wild animals. (1). Although it most frequently involves the liver and lungs, it can also localize in other parts of the

Corresponding Author: Yakup CAGLAROGLU yakup-caglaroglu@hotmail.com
Cite as: Caglaroglu Y, Elveren M, Temtek U, Kara CF. A 30-year single-center experience with ıntracranial hydatid cysts: Clinical and surgical outcomes of 50 cases. Turk J Clin Res. 2025;1(1):21-28

Content of this journal is licensed under a Creative Commons Attribution-NonCommercial-NonDerivatives 4.0 International License

Received: 27 Apr 2025 | **Accepted:** 25 May 2025 | **Published:** 30 May 2025

Turk J Clin Res. 2025;1(1):21-28
https://doi.org/10.63909/1453011

body such as the brain, heart, kidneys, and spinal cord (1–3). Intracranial involvement most commonly occurs in the supratentorial compartment, with a predilection for the parietal lobe supplied by the middle cerebral artery. (4). Cases confined to the brain account for only 1–2% of all hydatid disease and are more commonly seen in children (5). Surgery remains the preferred treatment modality; however, it is crucial to remove the lesion without rupture (6).

In our country, parasitic infections due to hydatid cysts are commonly observed, especially in rural areas (7). Despite the implementation of public health measures to control infectious diseases, the rate of human transmission remains high. The aim of this study is to reveal epidemiological and clinical differences by comparing cases treated in the last 20 years with those from earlier periods.

METHODS

This retrospective study was conducted by reviewing the medical records and radiological data of 50 patients who underwent surgical treatment for intracranial hydatid cysts at our clinic between 1993 and 2023. According to the year of surgery, the patients were divided into two groups: those who were operated between 1993 and 2003 were classified as Group A (n=34), and those who underwent surgery between 2003 and 2023 were classified as Group B (n=16). Ethical approval for this study was granted by the Ethics Committee of Atatürk University Faculty of Medicine (Date: 02.03.2025; Decision no: B.30.2.ATA.0.01.00).

Each patient received a neurological examination prior to surgery, which was subsequently complemented by imaging modalities such as computed tomography (CT) and magnetic resonance imaging (MRI). The typical CT findings for intracranial hydatid cysts were well-circumscribed, spherical or oval, hypodense lesions without pericystic edema or contrast enhancement. On MRI, the lesions appeared hypointense on T1-weighted and hyperintense on T2-weighted sequences, often surrounded by a hypointense capsule. In cases of suspected alveolar echinococcosis, additional MRI features such as multilobulation, irregular margins, peripheral contrast enhancement, and perilesional edema were noted.

Diagnosis was supported by serological testing in all cases, using ELISA and Indirect Hemagglutination Test. In addition, thoracic and abdominal CT scans were performed to evaluate extracranial involvement. All patients received preoperative albendazole therapy, which was continued postoperatively for at least 6 months.

Surgical treatment was performed under general anesthesia. The Dowling technique, which allows atraumatic, en bloc removal of the cyst via hydrodissection and gravity, was the preferred approach. In cases where the cyst ruptured intraoperatively, the surgical field was irrigated with hypertonic saline (3%), and postoperative albendazole therapy was extended. Postoperative radiological evaluation was conducted using serial CT or MRI for at least 12 months.

Statistical Analysis

All data were analyzed using SPSS software (version 21.0, Chicago, USA). Categorical variables (e.g., sex, lesion side, symptom frequencies) were compared using the chi-square (x^2) test. Continuous variables (e.g., age) were analyzed using the Student's t-test after assessment of normality. Statistical significance was defined as $p<0.05$. statistics were presented as mean±standard deviation (SD) for continuous variables and as frequencies and percentages for categorical variables. The Glasgow Outcome Score (GOS) was used to evaluate postoperative clinical outcomes.

RESULTS

This study encompassed 50 patients treated surgically for intracranial hydatid cysts over a 30-year span at our institution. The cohort was stratified into two groups according to the surgery date: Group A comprised 34 cases operated between 1993 and 2003, while Group B included 16 patients treated between 2003 and 2023. Demographic and clinical data of the patients are summarized in Table 1.

Turk J Clin Res. 2025;1(1):21-28
https://doi.org/10.63909/1453011

Table 1. Demographic and clinical characteristics of the patients

		Group A	Group B
Sex	Male	20	9
	Female	14	7
Mean age		32.0±13.6	22.3±14.2
Cyst location (Supratentorial)	Left	21	10
	Right	13	5
Presenting symptoms	Headache	26	13
	Altered consciousness	3	2
	Seizure	5	1

In terms of lesion laterality, cysts were more frequently located in the left hemisphere in both groups (Group A: 61.8%, Group B: 62.5%), with no significant difference (p=0.955, x^2 test). All lesions were supratentorial in both groups except for one case in Group B, which involved the posterior fossa (cerebellar localization).

The most common presenting symptom in both cohorts was headache, reported by 26 patients in Group A (76.5%) and 13 patients in Group B (81.3%) (p=0.715, x^2 test). Other symptoms included altered consciousness in 3 patients from Group A (8.8%) and 2 from Group B (12.5%), as well as seizures in 5 Group A patients (14.7%) and 1 Group B patient (6.3%). These differences were not statistically significant but reflect the known variability in symptomatology depending on lesion location and size.

Table 2 summarizes the comprehensive clinical and radiological profiles of patients in Group B. The age distribution ranged from 9 to 65 years, with 9 individuals (56.3%) being younger than 18. Multiple intracranial cysts were identified in 5 patients (31.3%). Reoperation was necessary in three cases (18.8%), and recurrence was confirmed in two of these. One individual required a second surgical intervention due to hepatic involvement. Extracranial dissemination, predominantly affecting the liver, was documented in three patients (18.8%).

Table 2. Clinical and radiological features of Group B patients

Age	Sex	Location	Number of lesions	Lesion size	Recurrence	Other system involvement	Reason for application	GOS
9	M	P	Only	9.5x10	-	-	Headache	5
10	M	P	Only	10x9	-	-	Headache	5
16	F	O	Only	5x7.5	+	Liver	Headache	5
65	M	P	Only	5x3	-	Liver	Disorientation	1
27	M	P	Only	6x6	-	-	Headache	5
16	M	P	Only	-	-	-	Headache	5
36	F	P	M	7x5 3x2	-	Liver	Headache	5
17	M	F,O	M	3x3 3x2 2x2	-	-	Disorientation	1
11	F	P	Only	6x6.5	-	-	Headache	5
27	M	O	M	5x6.5	-	-	Headache	5
30	F	F,P,O	M	4x4 4x2	+	-	Headache	5
16	M	P	Only	-	+	-	Headache	5
29	F	P	Only	5x5.5	-	-	Headache	5
14	F	P,T	M	5x4 9x3	-	-	Seizure	5
9	F	C	Only	4x3.5	-	-	Headache	5
26	M	P	Only	5.5x6	-	-	Headache	5

F: Female, E: Male, P: Parietal, O: Occipital, F: Frontal, T: Temporal, C: Cerebellar, M: Multiple, GOS: Glasgow Outcome Score

Turk J Clin Res. 2025;1(1):21-28
https://doi.org/10.63909/1453011

Radiological assessment was performed using both CT and MRI in all patients. On CT, the cysts appeared as well-circumscribed, large, spherical or oval, hypodense lesions with no contrast enhancement or pericystic edema. The internal density was similar to cerebrospinal fluid. MRI revealed hypointensity on T1-weighted images and hyperintensity on T2-weighted sequences, often surrounded by a hypointense rim and showing smooth, regular contours (Figures 1–3). In patients with alveolar-type cysts (n=2), the lesions appeared multilobulated with irregular margins, perilesional edema, and contrast enhancement, which are distinguishing features (Figure 4).

In the two patients with alveolar-type echinococcosis, both lesions exhibited aggressive radiological features including multilobulation, contrast enhancement, and surrounding edema. One of these patients, a 65-year-old male, presented with altered consciousness and died in the early postoperative period despite aggressive surgical and medical management. The other, a 36-year-old female with multiple parietal and occipital lesions, underwent successful total excision with no recurrence



Figure 2. T1-weighted MRI image displaying a sharply circumscribed, non-enhancing cystic lesion in the parietal lobe with hypointense signal intensity and smooth margins

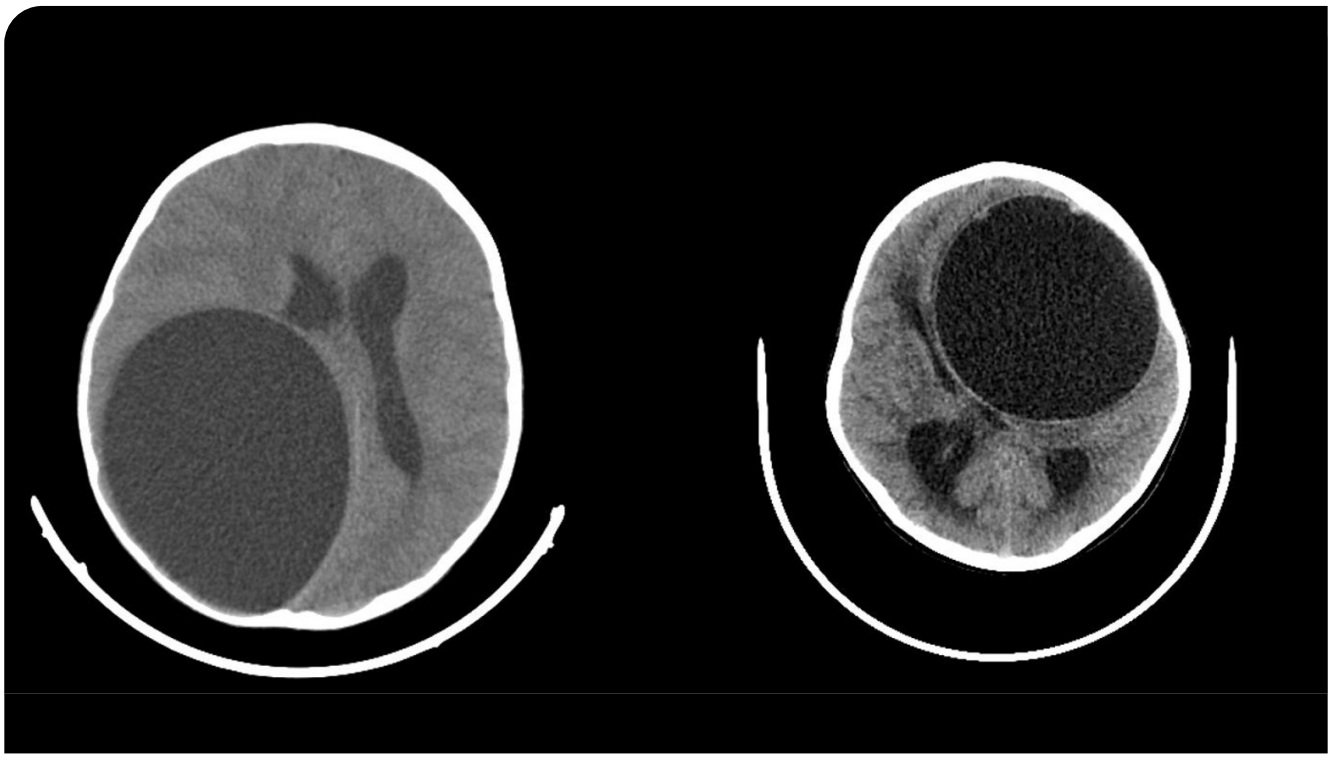

Figure 1. Axial brain CT image showing a well-defined, large, hypodense cystic lesion with no contrast enhancement or surrounding edema. The lesion causes significant midline shift due to mass effect

Turk J Clin Res. 2025;1(1):21-28
https://doi.org/10.63909/1453011

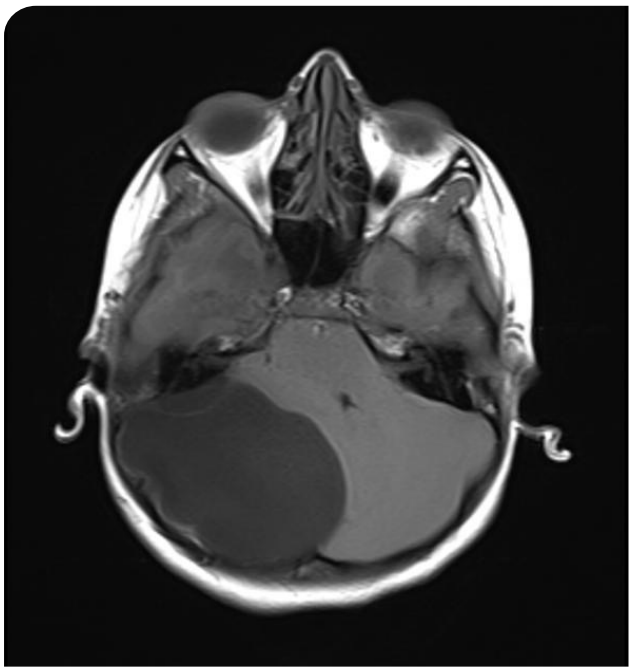

Figure 3. T2-weighted MRI revealing a large, well-defined cystic lesion localized in the posterior fossa, causing brainstem compression and distortion of the fourth ventricle

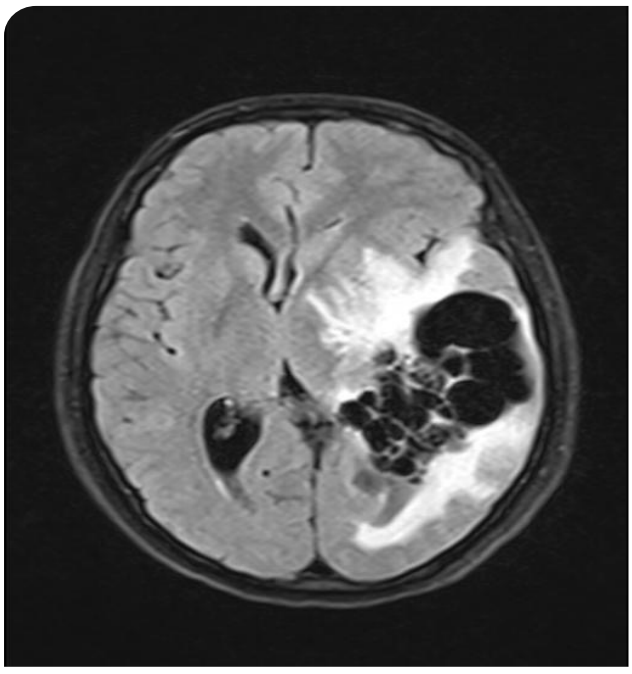

Figure 4. MRI of a patient with histologically confirmed alveolar-type hydatid cyst showing a multilobulated, irregularly bordered lesion with surrounding edema and mild contrast enhancement—features suggestive of invasive disease

observed during the one-year follow-up. The aggressive nature and higher morbidity associated with alveolar-type lesions underscore the importance of early detection and complete surgical excision in such cases.

Surgical treatment was performed in all patients using an approach tailored to the anatomical location of the lesion. The Dowling technique, based on hydrodissection and gravity-aided delivery, was employed in 14 patients in Group B (87.5%) for intact cyst removal. In two patients (12.5%), intraoperative rupture of the cyst occurred. In these cases, the surgical field was irrigated thoroughly with hypertonic saline to reduce the risk of secondary dissemination, and prolonged albendazole therapy was initiated postoperatively.

All individuals in Group B were monitored during the postoperative period. A Glasgow Outcome Score (GOS) of 5, reflecting favorable recovery, was recorded in 14 patients (87.5%). Conversely, two patients (12.5%) succumbed in the early postoperative phase, primarily due to severe complications such as extensive lesion volume, increased intracranial pressure, and compression of the brainstem. Follow-up imaging over a one-year period revealed no recurrence in the surviving cases.

DISCUSSION

Intracranial hydatid cysts account for 1–2% of all hydatid disease cases and are more frequently observed in children and young adults (5, 9, 10). Consistent with the literature, 75% of patients in our study were under the age of 30. When comparing the two cohorts in our study, we observed a statistically significant decrease in mean age over time, from 32.0±13.6 years in Group A to 22.3±14.2 years in Group B (p=0.018). Despite this decrease in average age, the proportion of pediatric patients (under 18 years) remained relatively stable between the two groups (70.6% vs. 56.3%, p=0.366). This suggests that although overall public health measures and eradication programs may have contributed to lowering the general disease incidence, the disease still predominantly affects the pediatric and adolescent population.

While hydatid cysts are typically solitary lesions, multiple intracranial cysts may be encountered, especially in cases of previous rupture or dissemination (12, 13). In our series, multiple cysts were detected in

Turk J Clin Res. 2025;1(1):21-28
https://doi.org/10.63909/1453011

31.25% of Group B patients. This rate appears higher than commonly reported in the literature, possibly due to increased radiological awareness and improved imaging modalities. It has been proposed that secondary dissemination may occur following traumatic, surgical, or spontaneous rupture of a primary lesion (14).

Hydatid cysts can occur in any region of the brain, but they are most commonly localized in the supratentorial compartment, particularly the parietal lobe within the middle cerebral artery territory (9, 10). Our findings are consistent with this distribution: in both groups, cysts predominantly involved the parietal region, and the majority were located in the left hemisphere (Group A: 61.8%, Group B: 62.5%). This left hemispheric dominance has also been reported in previous series (13), although the clinical relevance remains unclear.

The most common clinical presentation in our cohort was headache, observed in 76.5% of Group A and 81.3% of Group B patients. No statistically significant difference was found between the groups (p=0.715). This aligns with previous studies indicating that headache is the most frequent symptom, likely due to increased intracranial pressure caused by the expanding cystic lesion (5, 16). Other symptoms such as altered consciousness and seizures were less common and showed no significant change over time.

Radiological evaluation remains critical in diagnosis. On CT, the cysts typically appear as spherical, hypodense, non-enhancing lesions without perilesional edema (17). On MRI, they are hypointense on T1 and hyperintense on T2-weighted images with a thin peripheral hypointense rim, which helps in differentiating them from other cystic lesions such as abscesses or cystic tumors (9, 18). In our series, alveolar echinococcosis was confirmed in two patients based on radiological and histopathological features. These lesions showed multilobulation, contrast enhancement, and surrounding edema—findings consistent with the literature (19).

Differential diagnosis includes arachnoid and porencephalic cysts, cystic neoplasms, and abscesses. Hydatid cysts can often be distinguished by their characteristic imaging features—most notably the absence of enhancement and perilesional edema, and their typically spherical shape (9). However, in alveolar forms, this distinction becomes more challenging due to their irregular appearance and inflammatory reaction (19).

While serological tests such as ELISA and Western blot support the diagnosis, false negatives may occur due to the limited immune response within the brain parenchyma (21). Thus, definitive diagnosis is usually confirmed histopathologically (22).

Surgical treatment remains the mainstay of management, with the primary goal being the complete and intact removal of the cyst to avoid recurrence, dissemination, or anaphylaxis (6, 12). The Dowling technique, involving careful hydrodissection and gravitational assistance, is widely preferred and was successfully employed in 87.5% of Group B patients in our study. Intraoperative rupture occurred in two cases (12.5%), necessitating copious irrigation with hypertonic saline and prolonged albendazole therapy. These findings are consistent with other surgical series reporting rupture rates ranging from 10–20% (16). Postoperative mortality was observed in two patients in Group B (12.5%), both of whom had large lesions with associated midline shift and deterioration in consciousness. Such outcomes reflect the previously reported complication of cortical collapse following removal of large cysts, which can lead to fatal outcomes (23, 24).

Albendazole therapy, administered both pre- and postoperatively, is known to reduce cyst wall tension, aid in sterilization, and reduce the risk of recurrence (25). No new recurrences were detected in the remaining Group B patients during follow-up, suggesting effective surgical and medical management.

Limitations

This study has several limitations. First, its retrospective design and single center setting may limit the generalizability of the findings. Second, the number of patients in Group B was relatively small, potentially affecting statistical power. Finally, missing data in a few cases particularly regarding lesion size or long term follow up may have introduced bias. Future multicenter, prospective studies with larger cohorts and standardized protocols are needed to confirm and expand upon these results.

Turk J Clin Res. 2025;1(1):21-28
https://doi.org/10.63909/1453011

CONCLUSION

Intracranial hydatid cyst remains an important differential diagnosis in space-occupying brain lesions, particularly in endemic regions and pediatric populations. Although the total number of cases has declined over the years, our findings show that the disease continues to affect children and young adults at a consistent rate. The observed decrease in mean age at presentation suggests improved diagnostic access and earlier detection.

Radiological imaging, especially MRI, remains essential for diagnosis, and serological testing may aid confirmation. Surgical excision without rupture, ideally using the Dowling technique, remains the cornerstone of effective treatment. Postoperative outcomes were favorable in most cases, although mortality due to mass effect and cyst size remains a concern in select patients. Albendazole therapy provides important adjunctive support in both pre- and postoperative settings. Ongoing public health interventions and early imaging are vital in reducing disease burden, while surgical precision continues to determine prognosis.

Acknowledgement: None.

Ethical Approval: Ethical approval for this study was granted by the Ethics Committee of Atatürk University Faculty of Medicine (Date: 02.03.2025; Decision no: B.30.2.ATA.0.01.00).

Author Contributions: Idea/Concept: Y.C., M.E.; Design: Y.C., M.E.; Supervision: Y.C., M.E.; Resources: Y.C., U.T.; Materials: M.E., U.T.; Data Collection and/or Processing: M.E., C.F.K.; Analysis and/or Interpretation: M.E., C.F.K.; Literature Review: M.E., U.T.; Written: Y.C.; Critical Reviews: Y.C., M.E.

Conflict of Interest: There is no conflict of interest between authors.

Financial Disclosure: There is no financial support or funding for this study.

References

1. Agudelo Higuita NI, Brunetti E, McCloskey C. Cystic echinococcosis. J Clin Microbiol. 2016;54(3):518-23.
2. Andronikou S, Welman CJ, Kader E. Classic and unusual appearances of hydatid disease in children. Pediatr Radiol. 2002;32(11):817-28.
3. Dahniya M, Hanna R, Ashebu S, Muhtaseb S, El-Beltagi A, Badr S, et al. The imaging appearances of hydatid disease at some unusual sites. Br J Radiol. 2001;74(879):283-9.
4. Polat P, Kantarci M, Alper F, Suma S, Koruyucu MB, Okur A. Hydatid disease from head to toe. Radiographics. 2003;23(2):475-94.
5. Ersahin Y, Mutluer S, Güzelbag E. Intracranial hydatid cysts in children. Neurosurgery. 1993;33(2):219-25.
6. Ciurea A, Fountas K, Coman T, Machinis T, Kapsalaki E, Fezoulidis N, et al. Long-term surgical outcome in patients with intracranial hydatid cyst. Acta Neurochir. 2006;148(4):421-6.
7. Avcioglu H, Bia MM, Balkaya I, Kirman R, Akyuz M, Guven E. Cystic echinococcosis in slaughtered sheep in Erzurum province, Turkey. Acta Tropica. 2022:106559.
8. Kantzanou M, Karalexi MA, Vassalos CM, Kostare G, Vrioni G, Tsakris A. Central nervous system cystic echinococcosis: a systematic review. Germs. 2022;12(2):283-91.
9. Bükte Y, Kemaloglu S, Nazaroglu H, Ozkan U, Ceviz A, Simsek M. Cerebral hydatid disease: CT and MR imaging findings. Swiss Med Wkly. 2004;134(31-32):459-67.
10. Köktekir E, Erdem Y, Gökçek C, Karatay M, Yilmaz A, Bayar MA, et al. Calcified intracranial hydatid cyst: case report. Turkish Journal of Parasitology. 2011;35(4):220-3.
11. Agrawal VM, Giri PJ. Largest intracranial calcified hydatid cyst: a case report with review of literature. Asian J Neurosurg. 2020;15(3):713-5.
12. Brahem M, Hlel K, Ayadi A, Bedoui A, Hmila F, Mahjoub B, et al. Cerebral hydatid cysts in children: 4 cases. Médecine et maladies infectieuses. 2006;36(8):434-7.
13. Tlili-Graiess K, El-Ouni F, Gharbi-Jemni H, Arifa N, Moulahi H, Mrad-Dali K, et al. Hydatidose cérébrale: aspects en imagerie. J Neuroradiol. 2006;33(5):304-18.
14. Al Zain TJ, Al-Witry SH, Khalili HM, Aboud SH, Al Zain FT Jr. Multiple intracranial hydatidosis. Acta Neurochir (Wien). 2002;144(11):1179-85.
15. Becher SB, Cheour M, Hassine LB, Hlioui S, Houas F, Ghram N, et al. Les kystes hydatiques cerebraux chez l'enfant. Archives de pédiatrie. 1997;4(11):1107-10.
16. Umerani MS, Abbas A, Sharif S. Intra cranial hydatid cyst: a case report of total cyst extirpation and review of surgical technique. J Neurosci Rural Pract. 2013;4(Suppl 1):125-8.
17. Wani NA, Kousar TL, Gojwari T, Robbani I, Singh M, Ramzan A, et al. Computed tomography findings in cerebral hydatid disease. Turk Neurosurg. 2011;21(3):347-51.
18. Duishanbai S, Jiafu D, Guo H, Liu C, Liu B, Aishalong M, et al. Intracranial hydatid cyst in children: report of 30 cases. Child's Nervous System. 2010;26(6):821-7.

Turk J Clin Res. 2025;1(1):21-28
https://doi.org/10.63909/1453011

19. Tunaci M, Tunaci A, Engin G, Özkorkmaz B, Ahishali B, Rozanes I. MRI of cerebral alveolar echinococcosis. Neuroradiology. 1999;41(11):844-6.
20. Menkü A, Kulaksizoglu O, Tucer B, Kurtsoy A, Akdemir H. Successful surgical excision of a gigantic cerebral hydatid cyst. Minim Invasive Neurosurg. 2004;47(1):61-4.
21. Nemati A, Kamgarpour A, Rashid M, Sohrabi Nazari S. Giant cerebral hydatid cyst in a child–a case report and review of literature. BJMP. 2010;3(3):338.
22. Handa U, Bal A, Mohan H. Cytomorphology of hydatid disease. Internet J Trop Med. 2005;2(1):102-4.
23. Kayaoglu C. Giant hydatid cyst in the posterior fossa of a child: a case report. JMIR. 2008;36(1):198-202.
24. Kadioğlu HH, Tüzün Y, Kayaoğlu ÇR, Aydin IH. Primary multiple hydatid cysts localizing in the petroclival area. J Clin Neurosci. 1998;5(4):447-50.
25. Per H, Kumandaş S, Gümüş H, Kurtsoy A. Primary soliter and multiple intracranial cyst hydatid disease: report of five cases. Brain Dev. 2009;31(3):228-33.