Turkish Journal of Clinical Research

Turk J Clin Res. 2025;1(1):66-70
https://doi.org/10.63909/1453010

CASE REPORT

Playing in her garden, a stray bullet

Kendi bahçesinde oynarken, maganda kurşunu

Abdullah Emre TACYILDIZ[1]

[1]Karabük University, Faculty of Medicine, Department of Neurosurgery, Karabük, Türkiye

Abstract

Aim: Firearm-related injuries and fatalities have been steadily increasing in the United States since 2014. While the intradural migration of bullets is well documented, paraspinal migration remains underreported. This case report presents a pediatric patient in whom a bullet migrated approximately 2–3 cm within the paraspinal muscles during the short interval between emergency department admission and surgical intervention. Our aim is to emphasize that even within a brief period, a bullet can change position within the musculature.

Methods: A six-year-old girl was admitted to the hospital after being struck by a stray celebratory bullet—commonly referred to in forensic literature as a "tired bullet"—while playing in her garden. She presented with severe back pain, shortness of breath, and facial ecchymosis. Neurological examination was normal. Imaging revealed the bullet located to the right of the T9 spinous process. To precisely localize the bullet and minimize incision size, a metal coin was taped to the left lateral aspect of the T9 spinous process, and a repeat dorsal X-ray was obtained. The patient was taken to the operating room under local anesthesia and placed in the prone position.

Results: Despite accurate preoperative localization, the bullet was not found directly beneath the planned incision. Within five minutes, it was noted that the bullet had migrated approximately 2–3 cm superiorly within the paraspinal musculature. The bullet was successfully removed, and the patient was discharged pain-free and neurologically intact the following day.

Conclusion: Although neurosurgeons are typically familiar with intraspinal bullet migration, this case demonstrates that migration can also occur within the paraspinal muscles. Intraoperative fluoroscopy following patient positioning is recommended for accurate localization. Furthermore, this case highlights the role—or at least the responsibility—of neurosurgeons in preventive public health advocacy, particularly in the context of pediatric firearm injuries.

Keywords: Paraspinal bullet migration, pediatric neurosurgery, stray bullet injury, intraoperative imaging, firearm safety.

Özet

Amaç: Ateşli silahlarla ilgili yaralanmalar ve ölümler, 2014 yılından bu yana Amerika Birleşik Devletleri'nde artış göstermektedir. Mermilerin intradural (dural zar içinde) göçü iyi belgelenmiş olsa da, paraspinal (omurga çevresi) göç daha az vurgulanmaktadır. Bu bildiride, acil servise başvuru ile cerrahi müdahale arasındaki kısa süre içinde merminin paraspinal kas içinde yaklaşık 2–3 cm göç ettiği pediatrik bir olguyu sunmaktayız. Amacimiz ise çok kısa sürelerde bile kas içinde ki merminin yer değiştirebileceğini vurgulamaktır.

Yöntemler: Altı yaşındaki bir kız çocuğu, bahçede oynarken rastgele atılan maganda kurşunu ile polislik literatüründe "yorgun merminin" isabet etmesi sonucu hastaneye başvurdu. Şiddetli sırt ağrısı, nefes darlığı ve yüzde ekimoz gibi şikayet ve bulgular mevcuttu. Nörolojik muayenesi normaldi. Görüntüleme, merminin T9 spinal çıkıntısının sağ yanında yer aldığını gösterdi. Merminin yerini tam olarak belirlemek ve kesi boyutunu en aza indirmek amacıyla, T9 spinal çıkıntının sol yan tarafına metal bir para bantlandı ve tekrar bir dorsal röntgen çekildi. Hasta lokal anestezi altında ameliyathaneye alındı ve pron (yüzüstü) pozisyonda yatırıldı.

Bulgular: İlk lokalizasyona rağmen, kesi hattının hemen altında mermiye ulaşılamadı. Beş dakika içinde, merminin paraspinal kas içinde beklenen yerin yaklaşık 2–3 cm üstüne yer değiştirdiği fark edildi. Mermi başarıyla çıkarıldı ve hasta ertesi gün ağrısız ve nörolojik bir defisit olmadan taburcu edildi.

Sonuç: Nörocerrahlar genellikle intraspinal mermi göçü ile aşina olsalar da, bu olgu paraspinal kaslar içinde de göç olabileceğini ortaya koymaktadır. Bu nedenle, doğru lokalizasyonun doğrulanması amacıyla, hastanın pozisyonlandırılmasından sonra intraoperatif floroskopi kullanımı önerilir. Ayrıca, bu olgu çocuklarda ateşli silahlarla ilişkili yaralanmalar bağlamında, nörocerrahların koruyucu halk sağlığı savunuculuğundaki rolünü vurgulamaktadır. Ya da en azından bu rolü de üstlenmeleri gerektiği kanaatindeyiz.

Anahtar Kelimeler: Paraspinal mermi göçü-hareketi, pediatrik beyin cerrahisi, yorgun mermi yaralanması, ameliyat içi görüntüleme, ateşli silah güvenliği.

INTRODUCTION

Treatment for spinal injuries includes advanced trauma life support, administration of antibiotics, fluid therapy, and, in selected cases, surgical intervention with bullet removal (1). Gun-related injuries and fatalities have been steadily increasing in the United States since 2014 (2). This alarming trend appears to be continuing in many parts of the world. Alarmingly, gunshot wounds are already among the top three causes of spinal cord injuries worldwide (3).

In rare cases, intradural migration of bullets has been reported (4). The literature includes cases documenting bullet migration from T10 to S1 and even from C1 to S2 (5-7).

Corresponding Author: Abdullah Emre TACYILDIZ abdullahemretacyildiz@gmail.com
Cite as: Tacyildiz E. Playing in her garden, a stray bullet. Turk J Clin Res. 2025;1(1):66-70

Content of this journal is licensed under a Creative Commons Attribution-NonCommercial-NonDerivatives 4.0 International License

Received: 25 Apr 2025 | **Accepted:** 21 May 2025 | **Published:** 30 May 2025

Turk J Clin Res. 2025;1(1):66-70
https://doi.org/10.63909/1453010

In this case report, we present the story of a 6-year-old girl who experienced both misfortune and unexpected fortune. She was unfortunate to be struck by a stray bullet while playing outdoors, yet fortunate that the bullet lodged beneath the fascia, within the muscle tissue, without damaging vital structures. These types of injuries are typically referred to in the medical literature as "celebratory gunfire injuries" (8). However, this terminology is arguably too mild and fails to convey the severity and recklessness involved. In Turkish, we use the expression "maganda kurşunu", which more accurately captures the cultural and emotional weight of such incidents. A more faithful translation might be "hooligan bullet" or even "brute's bullet," retaining the emotional and cultural weight of the original Turkish expression.

CASE REPORT

History

While playing in her garden, a 6-year-old girl suddenly experienced severe pain in her back and neck. Her mother also noticed bruising on her face and brought her to the emergency department with some initial complaints. A neurosurgical consultation was requested from our clinic. On neurological examination, the patient exhibited no motor or sensory deficits. However, a bullet entry wound was identified at approximately the C7 vertebral level (Figure 1A). Palpation over the C7 region revealed no palpable foreign body or bullet fragment.

Cervical and thoracic computed tomography confirmed the absence of any detectable foreign body in the cervical region and supported the presence of a bullet at a more caudal level (Figures 1A, 1B, and 1C). To localize the bullet with greater precision and minimize the surgical incision, a coin was taped to the left lateral aspect of the T9 spinous process, and a repeat dorsal X-ray was obtained (Figure 1D). With the family's informed consent, the patient underwent surgery for bullet removal.

Operation and Postoperative Course

The patient was placed in the prone position on the operating table under local anesthesia. Her back was cleansed four times with povidone-iodine solution and left to dry for five minutes. Sterile draping was applied, and the surgical field was carefully prepared. The incision site was determined based on the coin's location on the X-ray. A skin incision of approximately 3 cm was made, and a retractor was inserted. The fascia was incised using both scalpel and scissors. Manual exploration beneath the fascia was initially unsuccessful in locating the bullet (Figure 2).

Approximately five minutes later, the bullet—having migrated nearly 2 cm cranially—was identified and carefully extracted (Figure 3). Hemostasis was achieved using bipolar cautery. The fascia and skin layers were closed anatomically. The entire procedure lasted approximately 10–12 minutes.

Postoperatively, a pediatrician was consulted to manage pain and ensure appropriate fluid-electrolyte balance. The patient was discharged without pain the following day.

Following the procedure, the bullet was handed over to local law enforcement authorities. Police investigation revealed that the bullet was a ricochet and had already been discharged prior to impact.

No signs of infection, neurological deficit, or cerebrospinal fluid leakage were noted during follow-up. The patient remained asymptomatic and resumed normal activities within one week.

This case highlights the importance of prompt surgical intervention and multidisciplinary collaboration in the management of intracorporeal foreign bodies in pediatric patients.

DISCUSSION

While the management of spinal gunshot wounds remains a subject of ongoing debate, the circumstances surrounding our case are particularly unique (1, 9). Migration of a bullet within the intradural space is a rare but well-documented phenomenon familiar to neurosurgeons. In our case, however, the bullet migrated within the paraspinal muscle tissue—approximately 2–3 cm cranially—from the time the patient arrived at the emergency department until the time of surgical intervention. As a result, the initial incision site was misplaced. This highlights the importance of

Turk J Clin Res. 2025;1(1):66-70
https://doi.org/10.63909/1453010

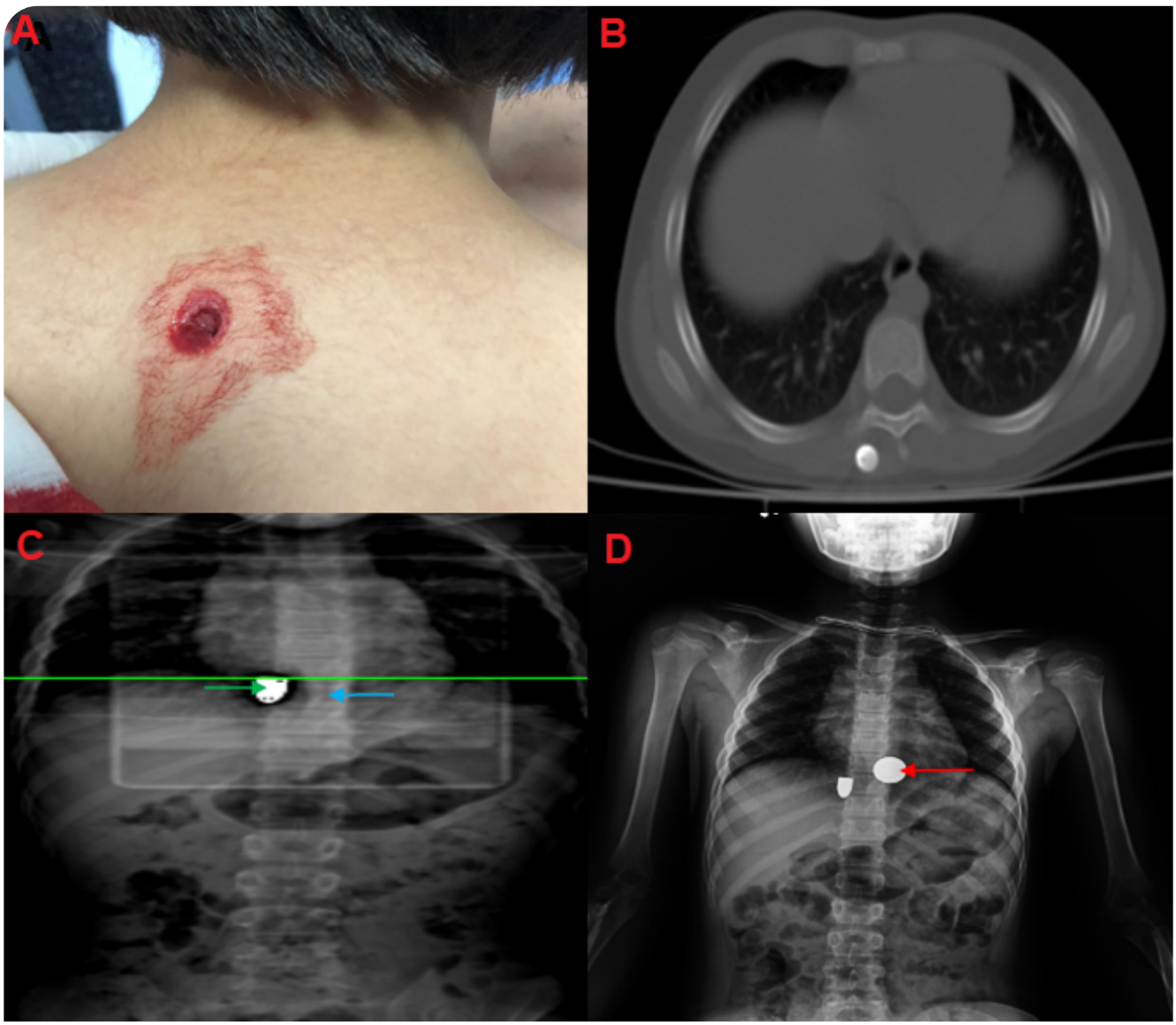

Figure 1. 1A. A bullet entry wound is visible at approximately the C7 level. 1B. The bullet is seen lateral to the T9 spinous process on computed tomography. 1C. The bullet (green arrow) is clearly visible on computed tomography; the T9 vertebra is indicated by the blue arrow. 1D. The coin (red arrow) placed on the patient's back to aid in localization is visible

intraoperative fluoroscopic confirmation rather than relying solely on static X-rays obtained in the emergency setting. Surgeons should remain aware that bullet migration, even within soft tissues such as muscle, can occur over short time intervals and significantly impact surgical planning.

Medicine is a universal profession, and like all other fields, neurosurgery faces global challenges (10,11). Physicians often stand against war and individual armament as a natural extension of medical ethics. A "hooligan bullet" injury can happen to anyone, anywhere in the world. In many countries, prevention programs are implemented to protect children from various types of injuries and accidents (12-14). Neurosurgeons should play a leading role in developing strategies to safeguard public health—particularly that of children and adolescents—by contributing to the design and implementation of evidence-based protective frameworks and algorithms

The rate of individual armament should be reduced through stricter regulatory measures. Individuals who

Turk J Clin Res. 2025;1(1):66-70
https://doi.org/10.63909/1453010

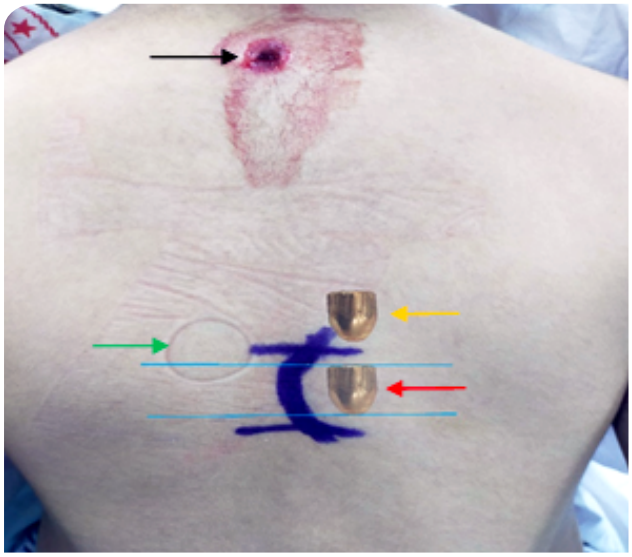

Figure 2. The bullet entry wound (black arrow) is shown. The predicted location of the bullet based on X-ray imaging is marked with a red arrow. The impression of the coin used for incision planning (green arrow) is also visible. The actual site of bullet removal is indicated by the orange arrow



Figure 3. The extracted bullet is shown following surgical removal

are permitted to carry firearms must undergo regular psychiatric evaluations. Their psychological status should be assessed periodically to ensure continued mental fitness and to prevent potential risks to public safety.

CONCLUSION

Bullet migration within the intradural space is a rare but well-recognized phenomenon in neurosurgery. However, as demonstrated in our case, migration can also occur within muscle tissue over very short periods of time. We recommend the routine use of intraoperative imaging, such as X-rays or fluoroscopy, to ensure accurate localization and minimize surgical error.

Beyond the operating room, neurosurgeons should recognize firearm-related injuries—particularly those affecting children—as a significant public health concern. Active involvement in preventive strategies and advocacy efforts is essential to address this growing societal issue.

Acknowledgement: None.

Ethical Approval: The participant provided both written and verbal consent for the use of their information in this case report (7 February 2022).

Author Contributions: Idea/Concept: A.E.T.; Design: A.E.T.; Supervision: A.E.T.; Resources: A.E.T.; Materials: A.E.T.; Data Collection and/or Processing: A.E.T.; Analysis and/or Interpretation: A.E.T.; Literature Review: A.E.T.; Written: A.E.T.; Critical Reviews: A.E.T.

Conflict of Interest: There is no conflict of interest in our study.

Financial Disclosure: No financial support was received in our study.

References

1. Siddiqui MI, Hawksworth SA, Sun DY. Removal of migrating lumbar spine bullet: case report and surgical video. World Neurosurg. 2019;131:62-4.
2. Iverson KR, Curtis E, Brown IE, Salcedo ES, Anderson JT. New fragmenting bullet leads to unexpected injury pattern: a case report involving the radically invasive projectile. Trauma. 2019;21(1):73-6.
3. Jaiswal M, Mittal RS. Concept of gunshot wound spine. Asian Spine J. 2013;7(4):359-64.
4. Baldawa S, Shivpuje V. Migratory low velocity intradural lumbosacral spinal bullet causing cauda equina syndrome. report of a case and review of literature. Eur Spine J. 2017;26(1):128-35.

Turk J Clin Res. 2025;1(1):66-70
https://doi.org/10.63909/1453010

5. Farrugia A, Raul Js, Géraut A, Ludes B. Ricochet of a bullet in the spinal canal: a case report and review of the literature on bullet migration. J Forensic Sci. 2010;55(5):1371-4.
6. Tanguy A, Chabannes J, Deubelle A, Vanneuville G, Dalens B. Intraspinal migration of a bullet with subsequent meningitis. J Bone Joint Surg Am. 1982;64(8):1244-5.
7. Young Jr W, Katz MR, Rosenwasser RH. Spontaneous migration of an intracranial bullet into the cervical canal. South Med J. 1993;86(5):557-9.
8. Alsabbagh Q, Kanaan T, Dumour EA, Hadidi F, Al-Sabbagh M. An incidental migrating intra-spinal bullet: the silent victim of celebratory gunfire. Br J Neurosurg. 2020;37(5):1358-61.
9. Kitchel SH, Research R. Current treatment of gunshot wounds to the spine. Clin Othop Relat Res. 2003;408:115-9.
10. Leidinger A, Extremera P, Kim EE, Qureshi MM, Young PH, Piquer J. The challenges and opportunities of global neurosurgery in East Africa. the Neurosurgery Education and Development model. Neurosurg Focus. 2018;45(4):e8
11. Servadei F, Rossini Z, Nicolosi F, Morselli C, Park KB. The role of neurosurgery in countries with limited facilities: facts and challenges. World Neurosurg. 2018;112:315-21.
12. Stracciolini A, Sugimoto D, Howell DR. Injury prevention in youth sports. Pediatr Ann. 2017;46(3):e99-e105.
13. Dias MS, Rottmund CM, Cappos KM, Reed ME, Wang M, Stetter C, et al. Association of a postnatal parent education program for abusive head trauma with subsequent pediatric abusive head trauma hospitalization rates. Jama Pediatr. 2017;171(3):223-9.
14. Falavigna A, Teles AR, Velho MC, Medeiros GS, Canabarro CT, de Braga GL, et al. Impact of an injury prevention program on teenagers' knowledge and attitudes: results of the Pense Bem–Caxias do Sul Project. J Neurosurg Pediatr. 2012;9(5):562-8.